2

Body Organization and Anatomical Nomenclature

Classification and Characteristics of Humans 000
Body Organization 000
Anatomical Nomenclature 000
Planes of Reference and Descriptive Terminology 000
Body Regions 000
Body Cavities and Membranes 000

Clinical Case Study Answer 000
Chapter Summary 000
Review Activities 000

Photo to Come

Clinical Case Study

A young woman was hit by a car while crossing a street. Upon arrival at the scene, paramedics found the patient to be a bit dazed but reasonably lucid, complaining of pain in her abdomen and the left side of her chest. Otherwise, her vital signs were within normal limits. Initial evaluation in the emergency room revealed a very tender abdomen and left chest. The chest radiograph demonstrated a collapsed left lung resulting from air in the pleural space (pneumothorax). The emergency room physician inserted a drainage tube into the left chest (into the pleural space) to treat the pneumothorax. Attention was then turned to the abdomen. Because of the finding of tenderness, a peritoneal lavage was performed. This procedure involves penetrating the abdominal wall and inserting a tube into the peritoneal cavity. Clear fluid such as sterile water or normal saline is then instilled into the abdomen and siphoned out again. The fluid used in this procedure is called lavage fluid. A return of lavage fluid containing blood, fecal matter, or bile indicates injury to an abdominal organ that requires surgery. The return of lavage fluid from this patient was clear. However, the nurse stated that lavage fluid was draining out of the chest tube.

From what you know about how the various body cavities are organized, do you suppose this phenomenon could be explained based on normal anatomy? What might have caused it to occur in our patient? Does the absence of bile, blood, etc., in the peritoneal lavage fluid guarantee that no organ has been ruptured? If it does not, explain why in terms of the relationship of the various organs to the membranes within the abdomen.

CLASSIFICATION AND CHARACTERISTICS OF HUMANS

Humans are biological organisms belonging to the phylum Chordata within the kingdom Animalia and to the family Hominidae within the class Mammalia and the order Primates.

Objective 1 Classify humans according to the taxonomic system.

Objective 2 List the characteristics that identify humans as chordates and as mammals.

Objective 3 Describe the anatomical characteristics that set humans apart from other primates.

The human organism, or *Homo sapiens*, as we have named ourselves, is unique in many ways. Our scientific name translates from the Latin to "man the intelligent," and indeed our intelligence is our most distinguishing feature. It has enabled us to build civilizations, conquer dread diseases, and establish cultures. We have invented a means of communicating through written symbols. We record our own history, as well as that of other organisms, and speculate about our future. We continue to devise ever more ingenious ways for adapting to our changing environment. At the same time, we are so intellectually specialized that we are not self-sufficient. We need one another as much as we need the recorded knowledge of the past.

We are constantly challenged to learn more about ourselves. As we continue to make new discoveries about our structure and function, our close relationship to other living organisms becomes more and more apparent. Often, it is sobering to realize our biological imperfections and limitations.

We share many characteristics with all living animals. As human organisms, we breathe, eat and digest food, excrete bodily wastes, locomote, and reproduce our own kind. We are subject to disease, injury, pain, aging, mutations, and death. Because we are composed of organic materials, we will decompose after death as microorganisms consume our flesh as food. The processes by which our bodies produce, store, and utilize energy are similar to those used by all living organisms. The genetic code that regulates our development is found throughout nature. The fundamental patterns of development of many nonhuman animals also characterize the formation of the human embryo.

In the classification, or taxonomic, system established by biologists to organize the structural and evolutionary relationships of living organisms, each category of classification is referred to as a *taxon*. The highest taxon is the kingdom and the most specific taxon is the species. Humans are species belonging to the animal kingdom. Phylogeny (*fi-loj'ĕ-ne*) is the science that studies relatedness on the basis of taxonomy.

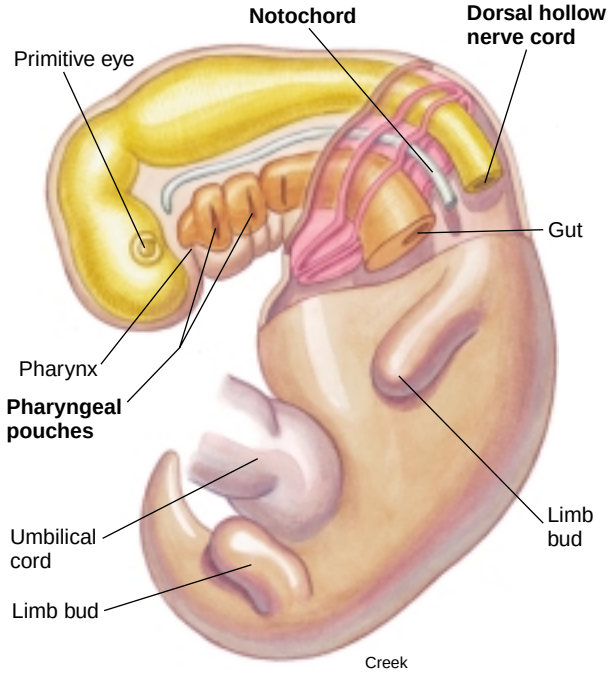

FIGURE 2.1 A schematic diagram of a chordate embryo. The three diagnostic chordate characteristics are indicated in boldface type.

Phylum Chordata

Human beings belong to the phylum Chordata (*fi'lum kor-dă'tă*), along with fishes, amphibians, reptiles, birds, and other mammals. All chordates have three structures in common: a notochord (*no'to-kord*), a dorsal hollow nerve cord, and pharyngeal (*fă-rin'je-al*) pouches (fig. 2.1). These chordate characteristics are well expressed during the embryonic period of development and, to a certain extent, are present in an adult. The notochord is a flexible rod of tissue that extends the length of the back of an embryo. A portion of the notochord persists in the adult as the nucleus pulposus, located within each intervertebral disc (fig. 2.2). The dorsal hollow nerve cord is positioned above the notochord and develops into the brain and spinal cord, which are supremely functional as the central nervous system in the adult. Pharyngeal pouches form gill openings in fishes and some

taxon: Gk. *taxis*, order

phylogeny: L. *phylum*, tribe; Gk. *logos*, study

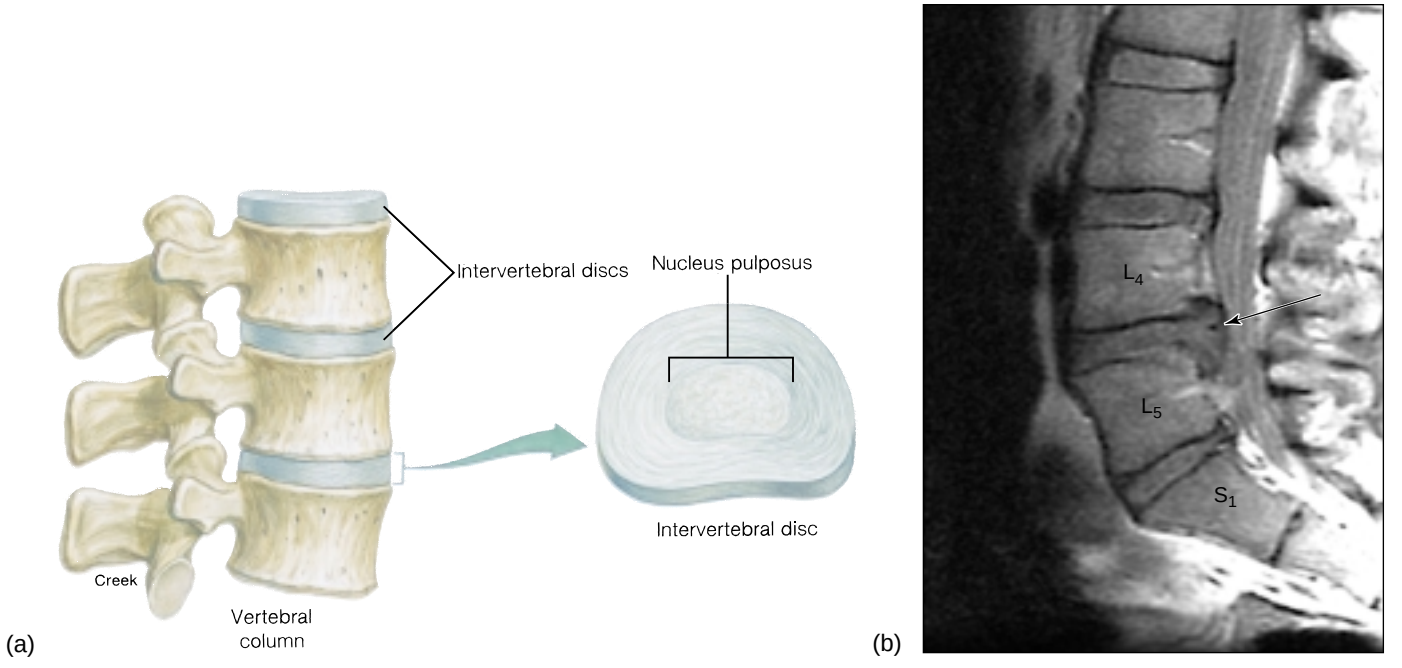

FIGURE 2.2 (*a*) A lateral view of the vertebral column showing the intervertebral discs and, to the right, a superior view of an intervertebral disc showing the nucleus pulposus and (*b*) a herniatod disc compressing a spinal nerve.

amphibians. In other chordates, such as humans, embryonic pharyngeal pouches develop, but only one of the pouches persists, becoming the middle-ear cavity. The **auditory** (eustachian) (*yoo-sta'shun*) **tube**, is a persisting connection between the middle-ear cavity and the **pharynx** (*far'ingks*) (throat area).

The function of an intervertebral disc and its nucleus pulposus is to allow flexibility between vertebrae for movement of the entire spinal column while preventing compression. Spinal nerves exit between vertebrae, and the discs maintain the spacing to avoid nerve damage. A "slipped disc," resulting from straining the back, is a misnomer. What actually occurs is a herniation, or rupture, because of a weakened wall of the nucleus pulposus. This may cause severe pain as a nerve is compressed.

Class Mammalia

Mammals are chordate animals with hair and mammary glands. Hair is a thermoregulatory protective covering for most mammals, and mammary glands serve for suckling the young (fig. 2.3). Other characteristics of mammals include three auditory ossicles (bones), heterodont dentition (teeth of various shapes), squamosal-dentary jaw articulation (a joint between the lower jaw and skull), an attached placenta (*plă-cen'tă*), well-developed facial muscles, a muscular diaphragm, and a four-chambered heart with a left aortic arch (fig. 2.4).

Order Primates

There are several subdivisions of closely related groupings of mammals. These are called orders. Humans, along with lemurs, monkeys, and great apes, belong to the order called Primates. Members of this order have prehensile hands (fig. 2.5), digits modified for grasping, and relatively large, well-developed brains (fig. 2.6).

Family Hominidae

Humans are the sole living members of the family Hominidae. *Homo sapiens* is included within this family, to which all the varieties or ethnic groups of humans belong (fig. 2.7). Each "racial group" has distinguishing features that have been established in isolated populations over thousands of years. Our classification pedigree is presented in table 2.1.

Fostered by greater ease of travel and communication, more frequent contact between diverse cultures has led to a breakdown of some of the traditional barriers to interracial marriage. This may lead to a mixing of the "gene pool," so that distinct ethnic groups become less evident. Perhaps multiple ethnic ties in everyone's pedigree would help reduce cultural hostility and strife.

heterodont: Gk. *heteros*, other; *odontos*, tooth

placenta: L. *placenta*, flat cake

Primates: L. *primas*, first

prehensile: L. *prehensus*, to grasp

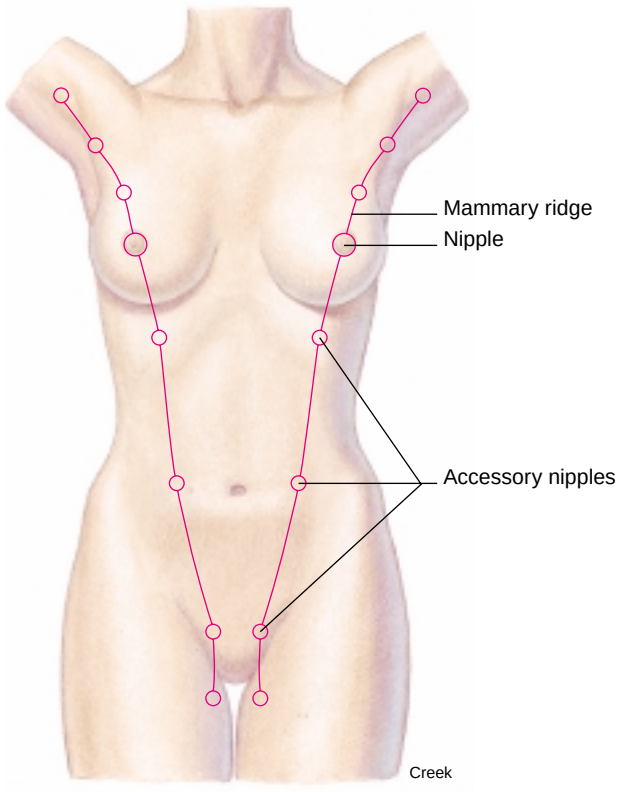

(a)

(b)

FIGURE 2.3 The mammary ridge and accessory nipples. (*a*) Mammary glands are positioned along a mammary ridge. (*b*) In humans, additional nipples (polythelia) occasionally develop elsewhere along the mammary ridge (see arrows).

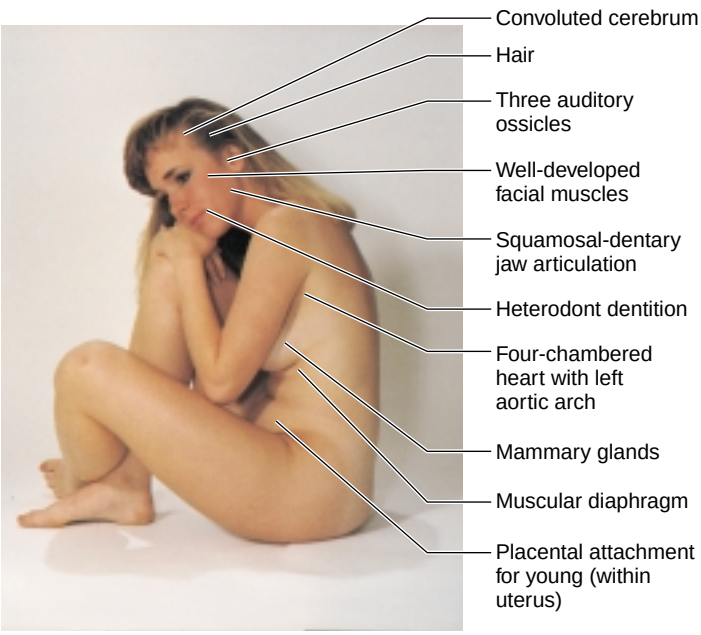

FIGURE 2.4 Mammals have several distinguishing characteristics; some of these are indicated in the photo with their approximate location within the body.

Characteristics of Humans

As human beings, certain of our anatomical characteristics are so specialized that they are diagnostic in separating us from other animals, and even from other closely related mammals. We also have characteristics that are equally well developed in other animals, but when these function with the human brain, they provide us with remarkable and unique capabilities. Our anatomical characteristics include the following:

1. **A large, well-developed brain.** The adult human brain weighs between 1,350 and 1,400 grams (3 pounds). This gives us a large brain-to-body-weight ratio. But more important is the development of portions of the brain. Certain extremely specialized regions and structures within the brain account for emotion, thought, reasoning, memory, and even precise, coordinated movement.
2. **Bipedal locomotion.** Because humans stand and walk on two appendages, our style of locomotion is said to be *bipedal*. Upright posture imposes other diagnostic structural features, such as the *sigmoid* (S-shaped) *curvature* of the

bipedal: L. *bi*, two; *pedis*, foot

sigmoid: Gk. *sigma*, shaped like the letter *S*

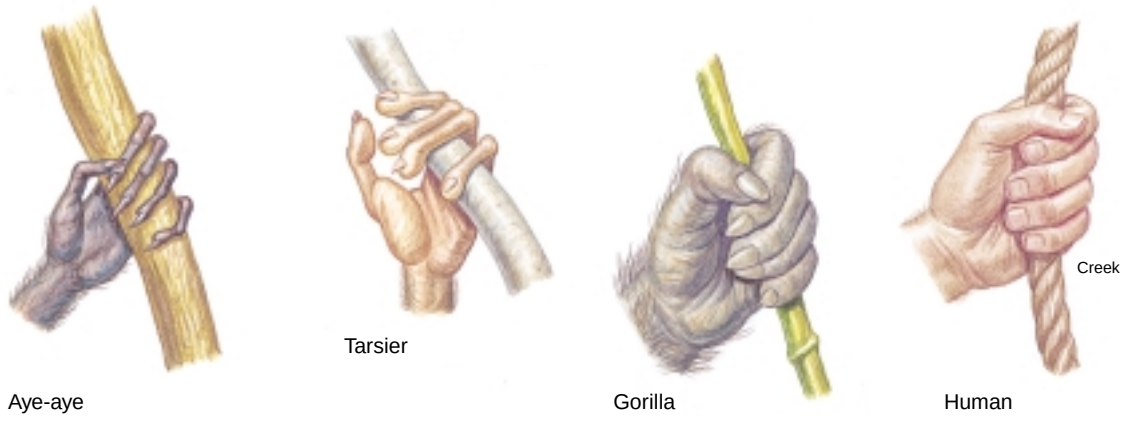

FIGURE 2.5 An opposable thumb enables a prehensile grip, which is characteristic of primates.

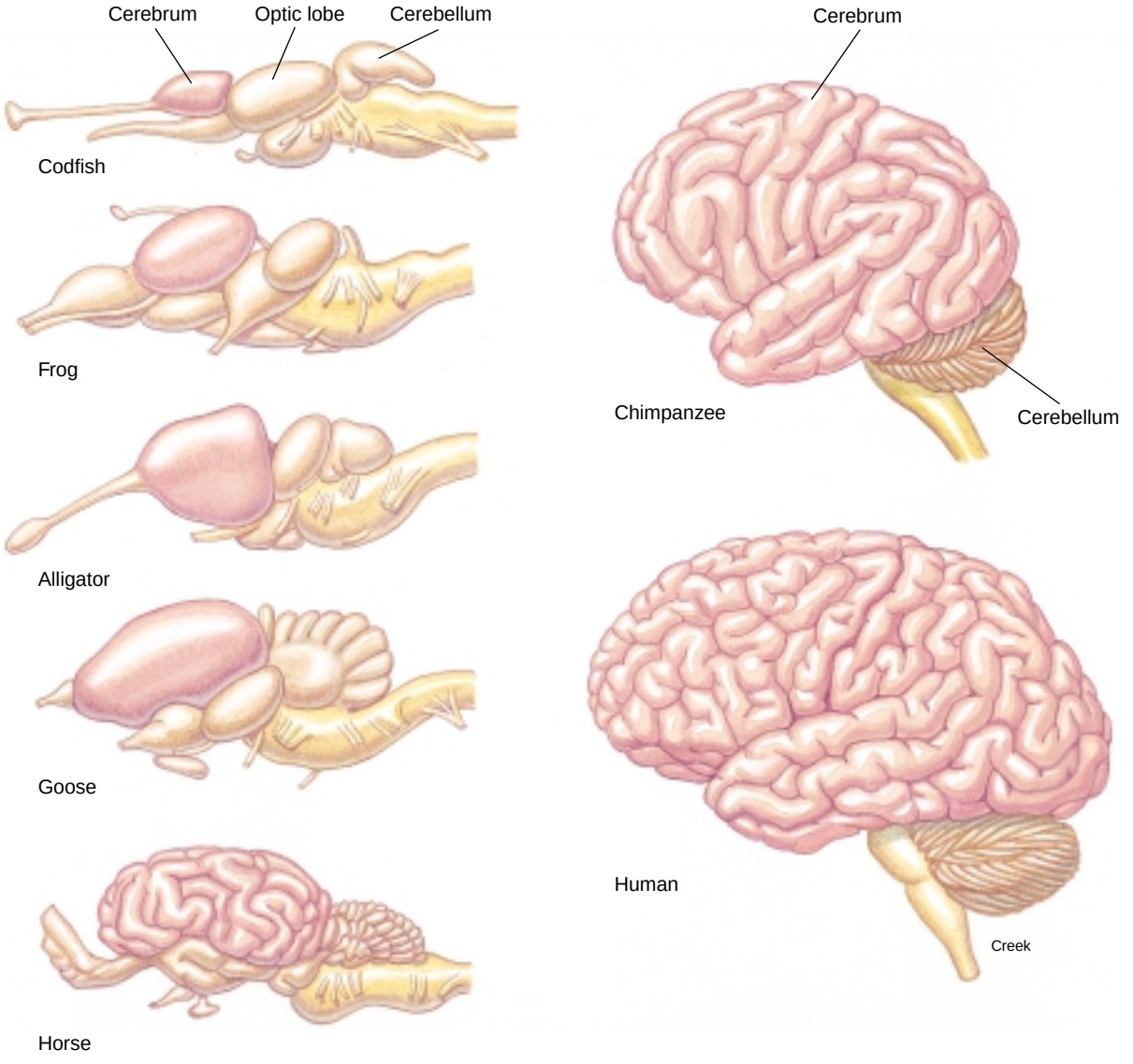

FIGURE 2.6 The brains of various vertebrates showing the relative size of the cerebrum (shaded pink) to other structures. (The brains are now drawn to scale. Note that only mammals have a convoluted cerebrum.)

FIGURE 2.7 The principal races of humans: (*a*) Mongoloid (Thailand), (*b*) Caucasoid (*c*) Negroid (Africa), (*d*) people of Indian subcontinent (Nepal), (*e*) Capoid (Kalahari bushman), and (*f*) Australoid (Ngatatjara man, West Australia).

TABLE 2.1 Classification of Human Beings

Taxon	Designated Grouping	Characteristics
Kingdom	Animalia	Eucaryotic cells without walls, plastids, or photosynthetic pigments
Phylum	Chordata	Dorsal hollow nerve cord; notochord; pharyngeal pouches
Subphylum	Vertebrata	Vertebral column
Class	Mammalia	Mammary glands; hair; convoluted cerebrum
Order	Primates	Well-developed brain; prehensile hands
Family	Hominidae	Large cerebrum, bipedal locomotion
Genus	*Homo*	Flattened face; prominent chin and nose with inferiorly positioned nostrils
Species	*sapiens*	Largest cerebrum

spine, the anatomy of the hips and thighs, and arched feet. Some of these features may cause clinical problems in older individuals.

3. **An opposable thumb.** The human thumb is structurally adapted for tremendous versatility in grasping objects. The saddle joint at the base of the thumb allows a wide range of movement (see fig. 8.13). All primates have opposable thumbs.
4. **Well-developed vocal structures.** Humans, like no other animals, have developed articulated speech. The anatomical structure of our vocal organs (larynx, tongue, and lips), and our well-developed brain have made this possible.
5. **Stereoscopic vision.** Although this characteristic is well developed in several other animals, it is also keen in humans. Our eyes are directed forward so that when we focus on an object, we view it from two angles. Stereoscopic vision gives us depth perception, or a three-dimensional image.

stereoscopic: Gk. *stereos*, solid; *skopein*, to view

We also differ from other animals in the number and arrangement of our vertebrae (vertebral formula), the kinds and number of our teeth (tooth formula), the degree of development of our facial muscles, and the structural organization of various body organs.

The human characteristics just described account for the splendor of our cultural achievements. As bipedal animals, we have our hands free to grasp and manipulate objects with our opposable thumbs. We can store information in our highly developed brain, make use of it at a later time, and even share our learning through oral or written communication.

Knowledge Check

1. What is a chordate? Why are humans considered members of the phylum Chordata?
2. Why are humans designated as vertebrates, mammals, and primates? What characteristics distinguish humans from other primates?
3. Which characteristics of humans are adaptive for social organization?

BODY ORGANIZATION

Structural and functional levels of organization characterize the human body, and each of its parts contributes to the total organism.

Objective 4 Identify the components of a cell, tissue, organ, and system, and explain how these structures relate to one another in constituting an organism.

Objective 5 Describe the general function of each system.

Cellular Level

The **cell** is the basic structural and functional component of life. Humans are multicellular organisms composed of 60 to 100 trillion cells. It is at the microscopic cellular level that such vital functions of life as metabolism, growth, irritability (responsiveness to stimuli), repair, and replication are carried on.

Cells are composed of **atoms**—minute particles that are bound together to form larger particles called **molecules** (fig. 2.8). Certain molecules, in turn, are grouped in specific ways to form small functional structures called **organelles** (*or"gă-nelz'*). Each organelle carries out a specific function within the cell. A cell's nucleus, mitochondria, and endoplasmic reticulum are organelles. The structure of cells and the functions of the organelles will be examined in detail in chapter 3.

cell: L. *cella*, small room

The human body contains many distinct kinds of cells, each specialized to perform specific functions. Examples of specialized cells are bone cells, muscle cells, fat cells, blood cells, and nerve cells. The unique structure of each of these cell types is directly related to its function.

Tissue Level

Tissues are layers or groups of similar cells that perform a common function. The entire body is composed of only four principal kinds of tissues: *epithelial*, *connective*, *muscular*, and *nervous tissue*. An example of a tissue is the muscle within the heart, whose function it is to pump the blood through the body. The outer layer of skin is a tissue (epithelium) because it is composed of similar cells that together serve as a protective shield for the body. *Histology* is the science concerned with the microscopic study of tissues. The characteristic roles of each tissue type are discussed fully in chapter 4.

Organ Level

An **organ** is an aggregate of two or more tissue types that performs a specific function. Organs occur throughout the body and vary greatly in size and function. Examples of organs are the heart, spleen, pancreas, ovary, skin, and even any of the bones within the body. Each organ usually has one or more primary tissues and several secondary tissues. In the stomach, for example, the inside epithelial lining is considered the primary tissue because the basic functions of secretion and absorption occur within this layer. Secondary tissues of the stomach are the connective, nervous, and muscle tissues.

System Level

The **systems** of the body constitute the next level of structural organization. A body system consists of various organs that have similar or related functions. Examples of systems are the circulatory system, nervous system, digestive system, and endocrine system. Certain organs may serve two systems. For example, the pancreas functions with both the endocrine and digestive systems and the pharynx serves both the respiratory and digestive systems. All the systems of the body are interrelated and function together, making up the *organism*.

tissue: Fr. *tissu*, woven; from L. *texo*, to weave

organ: Gk. *organon*, instrument

system: Gk. *systema*, being together

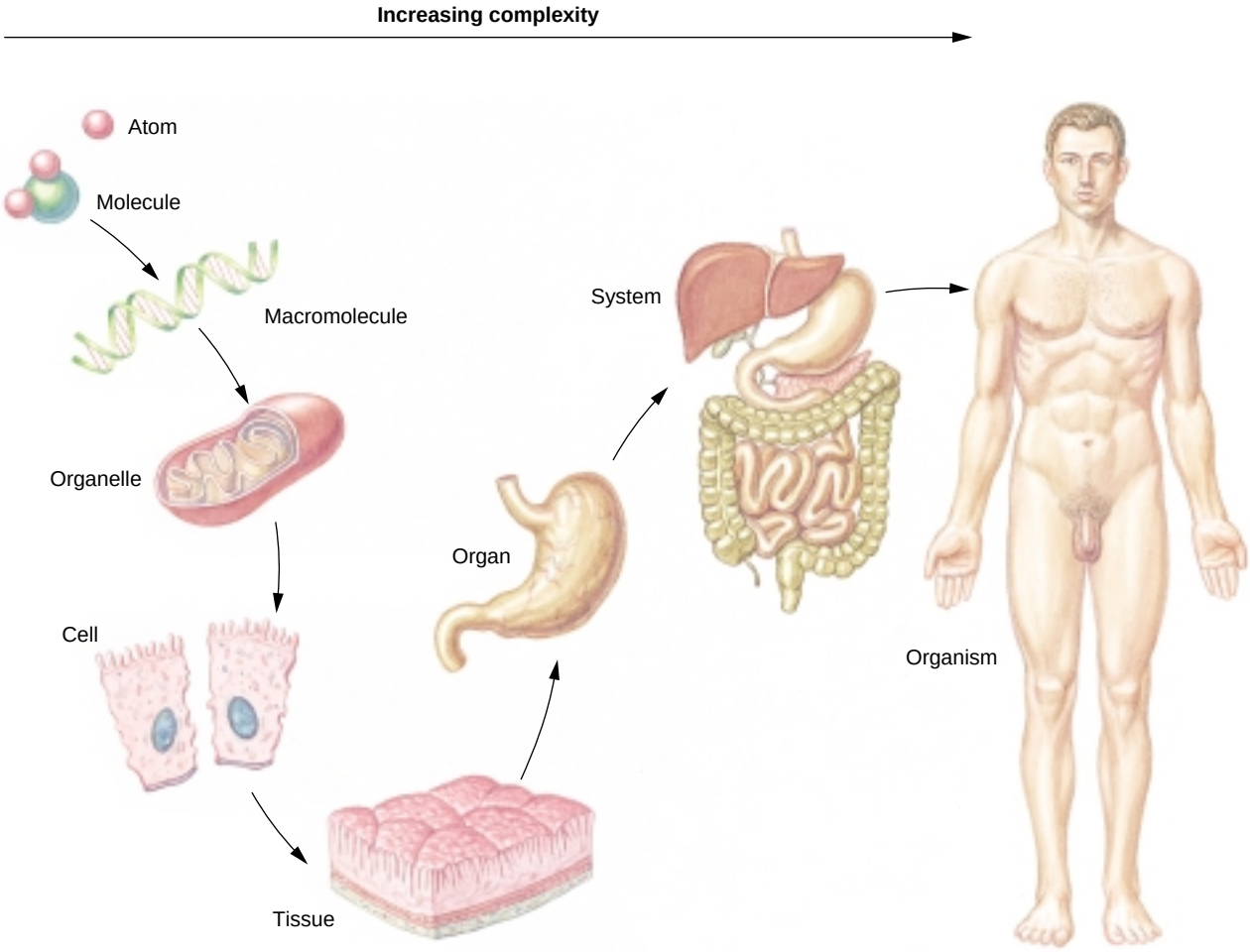

FIGURE 2.8 The levels of structural organization and complexity within the human body.

Growth is a normal process by which an organism increases in size as a result of the accretion of cells and tissues similar to those already present within organs. Growth is an integral part of development that continues until adulthood. Normal growth depends not only on proper nutrition but on the concerted effect of several hormones (chemicals produced by endocrine glands), including insulin, growth hormone, and (during adolescence) the sex hormones. It is through the growth process that each of the body systems eventually matures (fig. 2.9). *Puberty* is the developmental transition during the growth process when sexual features become expressed in several of the body systems and the reproductive organs become functional.

A *systematic (systemic) approach* to studying anatomy emphasizes the purposes of various organs within a system. For example, the functional role of the digestive system can be best understood if all of the organs within that system are studied together. In a *regional approach*, all of the organs and structures in one particular region are examined at the same time. The regional approach has merit in graduate professional schools (medical, dental, etc.) because the structural relationships of portions of several systems can be observed simultaneously. Dissections of cadavers are usually conducted on a regional basis. Trauma or injury usually affects a region of the body, whereas a disease that affects a region may also involve an entire system.

This text uses a systematic approach to anatomy. In the chapters that follow, you will become acquainted, system by system, with the functional anatomy of the entire body. An overview of the structure and function of each of the body systems is presented in figure 2.10.

Knowledge Check

4. Construct a diagram to illustrate the levels of structural organization that characterize the body. Which of these levels are microscopic?
5. Why is the skin considered an organ?
6. Which body systems control the functioning of the others? Which are supportive of the organism? Which serve a transportive role?

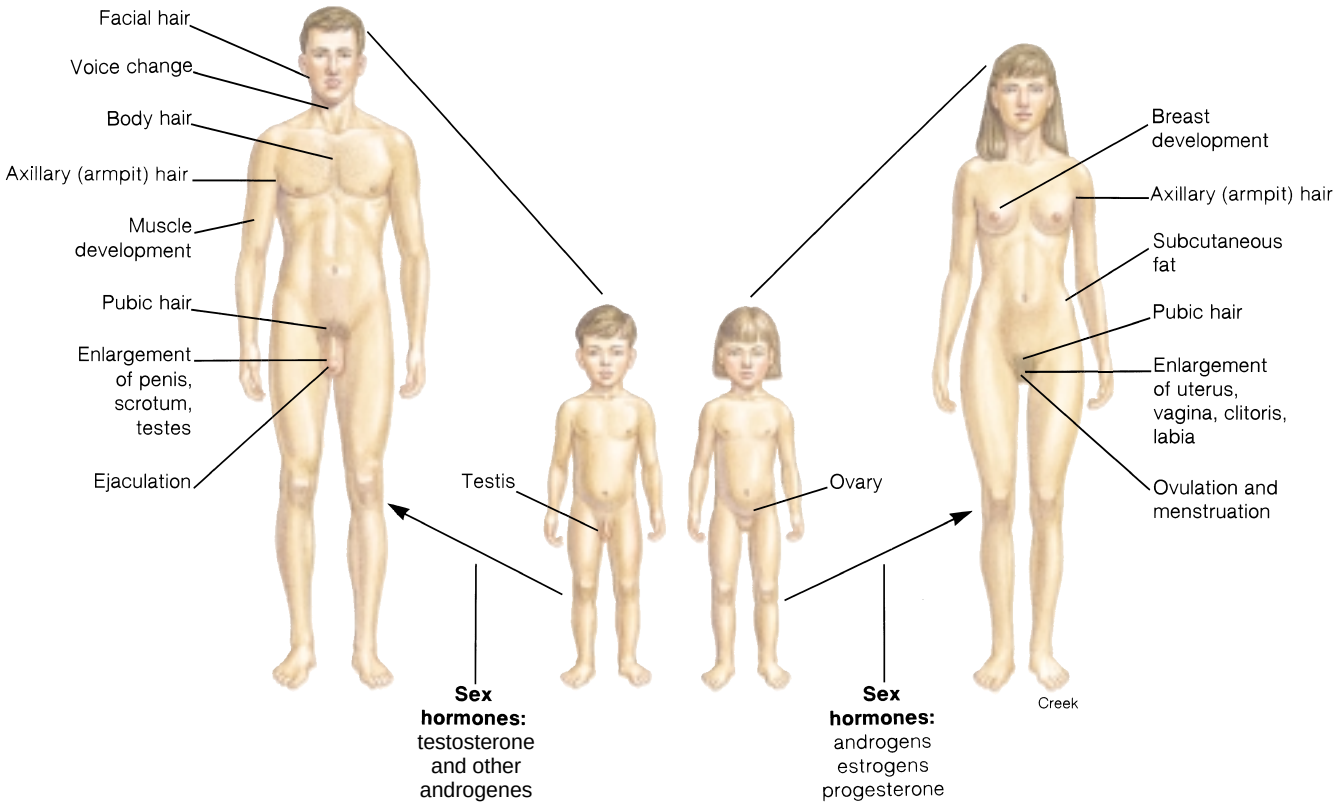

FIGURE 2.9 Developmental changes from childhood to adulthood. Controlled by hormones, puberty is the period of body growth when sexual characteristics are expressed and the sexual organs become functional.

ANATOMICAL NOMENCLATURE

In order to understand the science of anatomy, students must master its descriptive terminology.

Objective 6 Explain how anatomical terms are derived.

Objective 7 Describe what is meant by prefixes and suffixes.

Anatomy is a descriptive science. Analyzing anatomical terminology can be a rewarding experience in that one learns something of the character of antiquity in the process. However, understanding the roots of words is not only of academic interest. Familiarity with technical terms reinforces the learning process. Most anatomical terms are derived from Greek or Latin, but some of the more recent terms are of German and French origin. As mentioned in chapter 1, some anatomical structures bear the names of people who discovered or described them. Such terms are totally nondescriptive; unfortunately, they have little meaning in and of themselves.

Many Greek and Latin terms were coined more than 2,000 years ago. Deciphering the meanings of these terms affords a glimpse into our medical heritage. Many terms referred to common plants or animals. Thus, the term *vermis* means worm; *cochlea (kok'le-ă)*, snail shell; *cancer*, crab; and *uvula*, little grape. Even the term *muscle* comes from the Latin *musculus*, which means mouse. Other terms suggest the warlike environment of ancient Greece and Rome. *Thyroid*, for example, means shield; *xiphos (zi'fos)* means sword; and *thorax*, breastplate. *Sella* means saddle and *stapes (sta'pēz)* means stirrup. Various tools or instruments were referred to in early anatomy. The malleus and anvil resemble miniatures of a blacksmith's implements, and tympanum refers to a drum.

You will encounter many new terms throughout your study of anatomy. You can learn these terms more easily if you know the meaning of their prefixes and suffixes. Use the glossary of prefixes and suffixes (on the inside front cover) as an aid in learning new terms. Pronouncing these terms as you learn them will also help you remember them. A guide to the singular and plural forms of words is presented in table 2.2.

The material presented in the remainder of this chapter provides a basic foundation for anatomy, as well as for all medical and paramedical fields. Anatomy is a very precise science because of its universally accepted reference language for describing body parts and locations.

Knowledge Check

7. Explain the statement, Anatomy is a descriptive science.
8. Refer to the glossary of prefixes and suffixes on the front inside front cover to decipher the terms *blastocoel*, *hypodermic*, *dermatitis*, and *orchiectomy*.

Integumentary system
Function: external support and protection of body

Skeletal system
Function: internal support and flexible framework for body movement; production of blood cells

Muscular system
Function: body movement; production of body heat

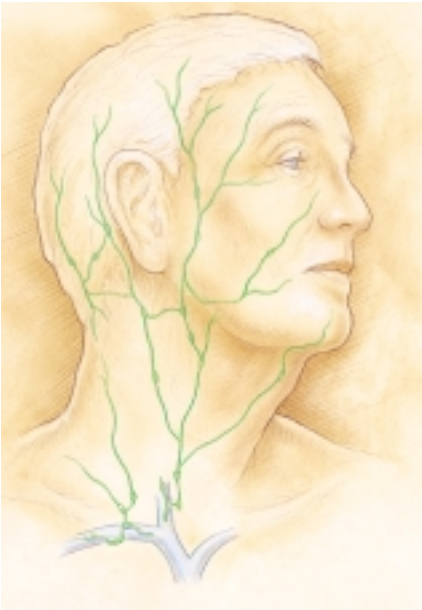

Lymphatic system
Function: body immunity; absorption of fats; drainage of tissue fluid

Endocrine system
Function: secretion of hormones for chemical regulation

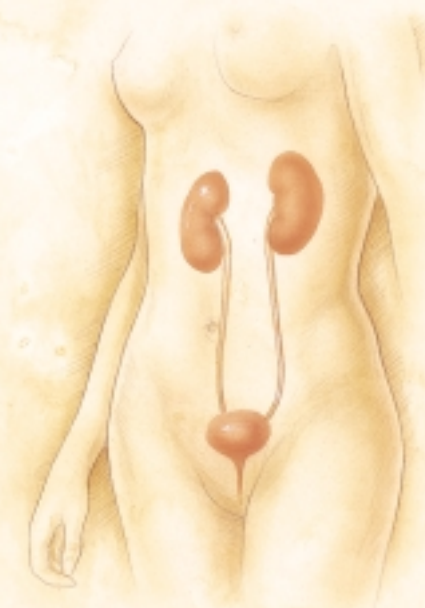

Urinary system
Function: filtration of blood; maintenance of volume and chemical composition of blood; removal of metabolic wastes from body

FIGURE 2.10 The body systems.

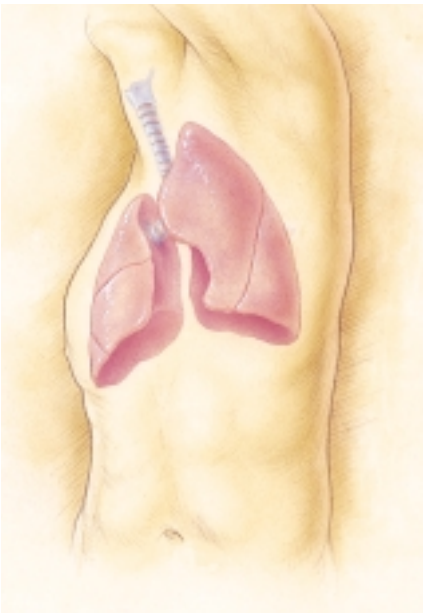

Respiratory system
Function: gaseous exchange between external environment and blood

Nervous system
Function: control and regulation of all other systems of the body

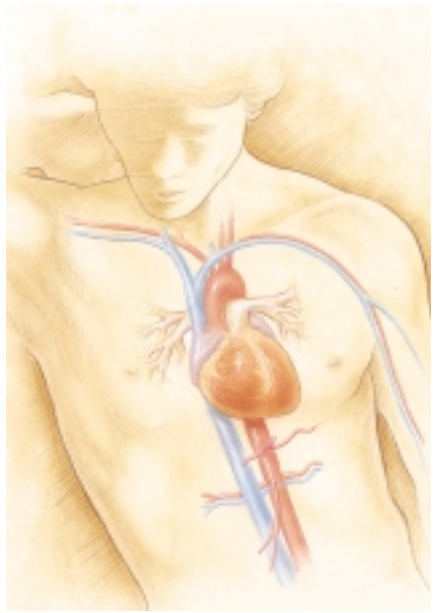

Circulatory system
Function: transport of life-sustaining materials to body cells; removal of metabolic wastes from cells

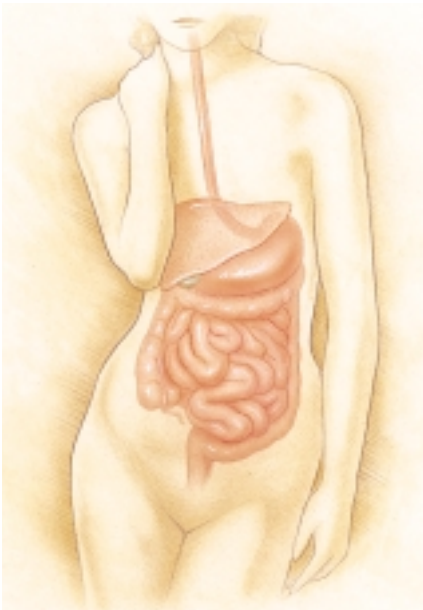

Digestive system
Function: breakdown and absorption of food materials

Female reproductive system
Function: production of female sex cells (ova); receptacle for sperm from male; site for fertilization of ovum, implantation, and development of embryo and fetus; delivery of fetus

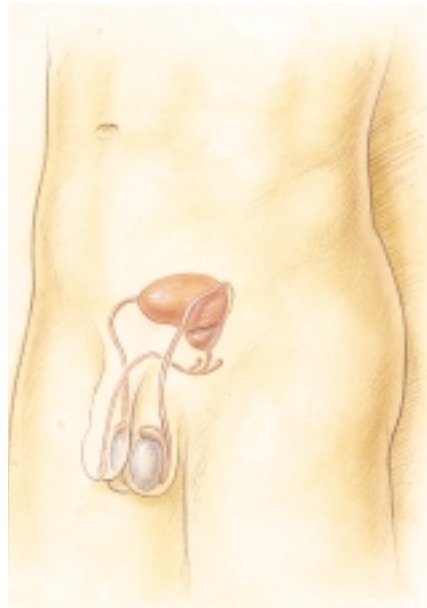

Male reproductive system
Function: production of male sex cells (sperm); transfer of sperm to reproductive system of female

FIGURE 2.10 The body systems.

TABLE 2.2 Examples of Singular and Plural Forms of Body Terminology

Singular ending	Plural ending	Examples
-a	-ae	Papilla, papilae; axilla, axillae
-en	-ina	Foramen, foramina; lumen, lumina
-ex	-ices	Cortex, cortices
-is	-es	Testis, testes
-is	-ides	Epididymis, epididymides
-ix	-ices	Matrix, matrices; appendix, appendices
-on	-a	Mitochondrion, mitochondria
-um	-a	Epithelium, epithelia; cilium, cilia; ovum, ova
-us	-i	Humerus, humeri; carpus, carpi; fasciculus, fasciculi
-us	-ora	Corpus, corpora
-x	-ges	Phalanx, phalanges; pharynx, pharynges
-y	-ies	Artery, arteries; ovary, ovaries

PLANES OF REFERENCE AND DESCRIPTIVE TERMINOLOGY

All of the descriptive planes of reference and terms of direction used in anatomy are standardized because of their reference to the body in anatomical position.

Objective 8 Identify the planes of reference used to locate structures within the body.

Objective 9 Describe the anatomical position.

Objective 10 Define and be able to properly use the descriptive and directional terms that refer to the body.

Planes of Reference

In order to visualize and study the structural arrangements of various organs, the body may be sectioned (cut) and diagrammed according to three fundamental planes of reference: a **sagittal** (saj'ĭ-tal) **plane**, a **coronal plane**, and a **transverse plane** (figs. 2.11 and 2.12). A sagittal plane extends vertically through the body dividing it into right and left portions. A *midsagittal (median) plane* is a sagittal plane that passes lengthwise through the midplane of the body, dividing it equally into right and left halves. Coronal, or *frontal*, planes also pass lengthwise and divide the body into anterior (front) and posterior (back) portions. Transverse planes, also called *horizontal*, or *cross-sectional*, *planes*, divide the body into superior (upper) and inferior (lower) portions.

coronal: L. *corona*, crown

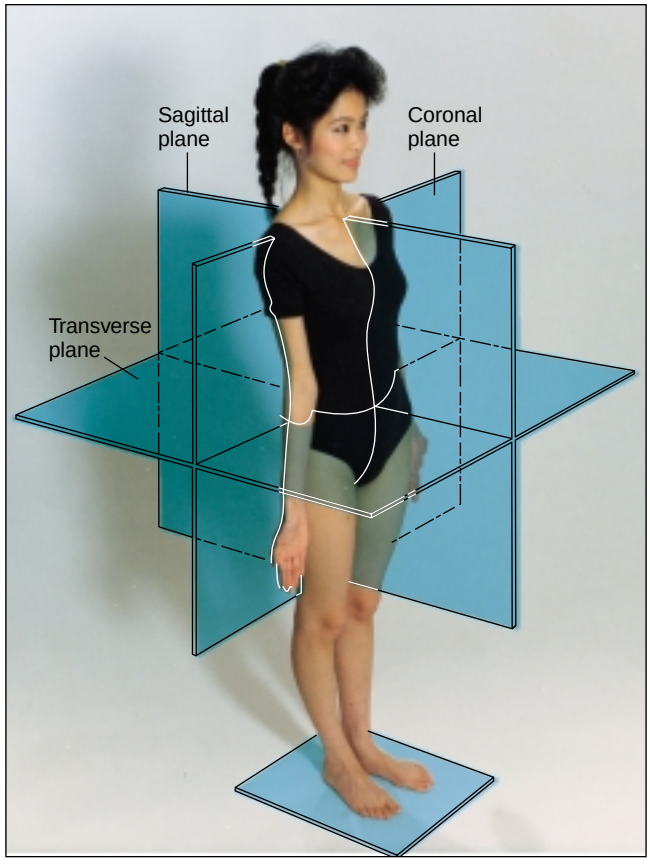

FIGURE 2.11 Planes of reference through the body.

The value of the computerized tomographic X-ray (CT) scan (see fig. 1.19*a*) is that it displays an image along a transverse plane similar to that which could otherwise be obtained only in an actual section through the body. Prior to the development of this technique, the vertical plane of conventional radiographs made it difficult, if not impossible, to assess the extent of body irregularities.

Descriptive Terminology

Anatomical Position

All terms of direction that describe the relationship of one body part to another are made in reference to the **anatomical position**. In the anatomical position, the body is erect, the feet are parallel to each other and flat on the floor, the eyes are directed forward, and the arms are at the sides of the body with the palms of the hands turned forward and the fingers pointed straight down (fig. 2.13).

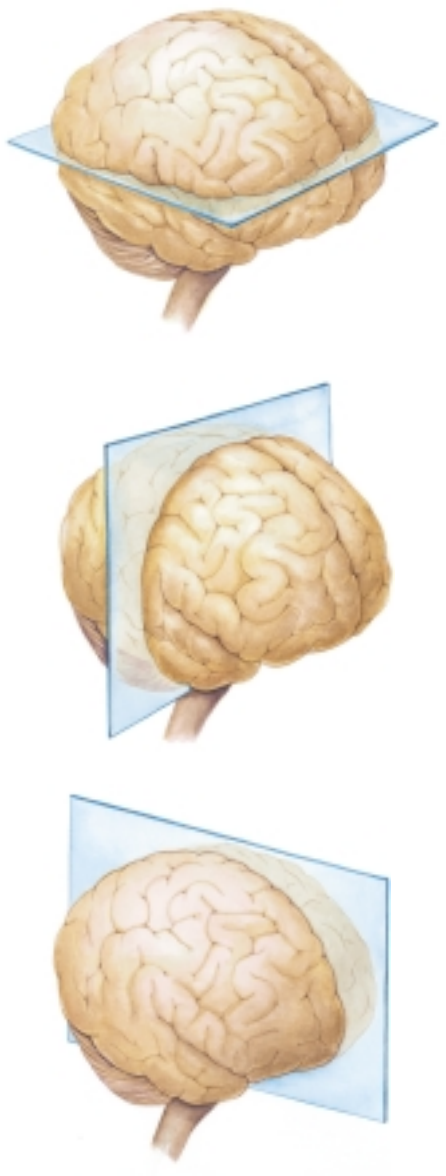

FIGURE 2.12 The human brain sectioned along (*a*) a transverse plane, (*b*) a coronal plane, and (*c*) a sagittal plane.

FIGURE 2.13 In the anatomical position, the body is erect, the feet parallel, the eyes directed forward, the arms to the sides with the palms directed forward, and the fingers pointed straight down.

Directional Terms

Directional terms are used to locate structures and regions of the body relative to the anatomical position. A summary of directional terms is presented in table 2.3.

Clinical Procedures

Certain clinical procedures are important in determining anatomical structure and function in a living individual. The most common of these are as follows:

- **Inspection.** Visually observing the body to note any clinical symptoms, such as abnormal skin color, swelling, or rashes. Other observations may include needle marks on the skin, irregular breathing rates, or abnormal behavior.
- **Palpation.** Applying the fingers with firm pressure to the surface of the body to feel surface landmarks, lumps, tender spots, or pulsations.
- **Percussion.** Tapping sharply on various locations on the thorax or abdomen to detect resonating vibrations as an aid in locating excess fluids or organ abnormalities.
- **Auscultation.** Listening to the sounds that various organs make (breathing, heartbeat, digestive sounds, and so forth).
- **Reflex testing.** Observing a person's automatic (involuntary) response to a stimulus. One test of a reflex mechanism involves tapping a predetermined tendon with a reflex hammer and noting the response.

Knowledge Check

9. Explain why a transverse plane through an organ is more important in studying specific systems than a transverse plane through the body.
10. What do we mean when we say that directional terms are relative and must be used in reference to a body structure or a body in anatomical position?

TABLE 2.3 Directional Terms for the Human Body

Term	Definition	Example
Superior (cranial, cephalic)	Toward the head; toward the top	The thorax is superior to the abdomen.
Inferior (caudal)	Away from the head; toward the bottom	The neck is inferior to the head.
Anterior (ventral)	Toward the front	The navel is on the anterior side of the body.
Posterior (dorsal)	Toward the back	The kidneys are posterior to the intestine.
Medial	Toward the midline of the body	The heart is medial to the lungs.
Lateral	Away from the midline of the body	The ears are lateral to the nose.
Internal (deep)	Away from the surface of the body	The brain is internal to the cranium.
External (superficial)	Toward the surface of the body	The skin is external to the muscles.
Proximal	Toward the trunk of the body	The knee is proximal to the foot.
Distal	Away from the trunk of the body	The hand is distal to the elbow.

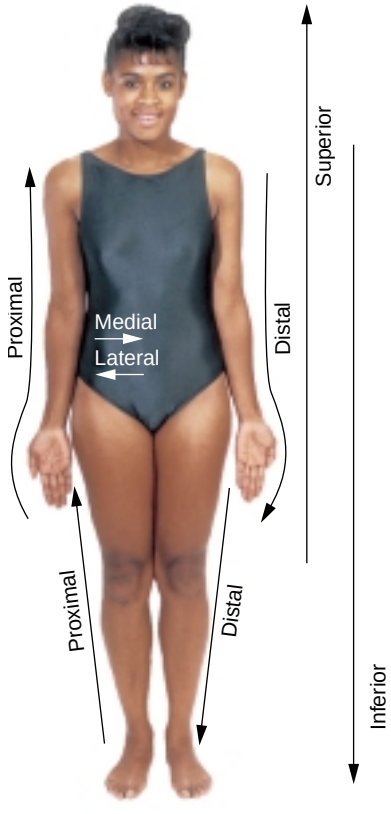

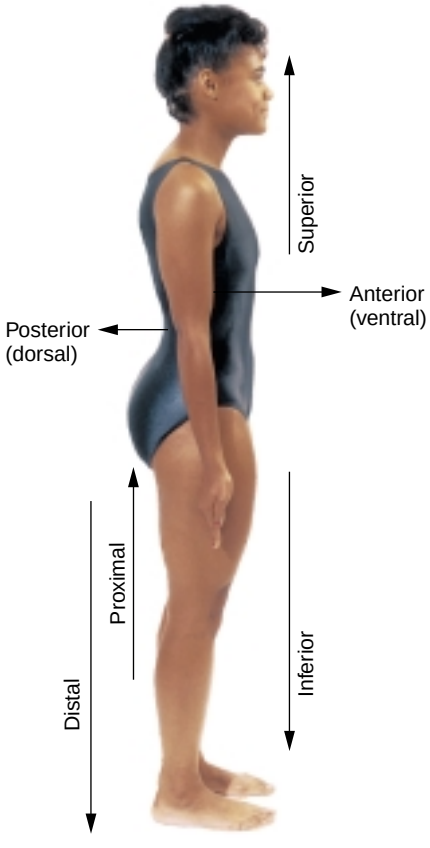

11. Write a list of statements, similar to the examples in table 2.3, that correctly express the directional terms used to describe the relative positions of various body structures.

BODY REGIONS

The human body is divided into regions and specific local areas that can be identified on the surface. Each region contains internal organs, the locations of which are anatomically and clinically important.

Objective 11 List the regions of the body and the principal local areas that make up each region.

Objective 12 Explain why it is important to be able to describe the body areas and regions in which major internal organs are located.

The human body is divided into several regions that can be identified on the surface of the body. Learning the terms that refer to these regions now will make it easier to learn the names of underlying structures later. The major body regions

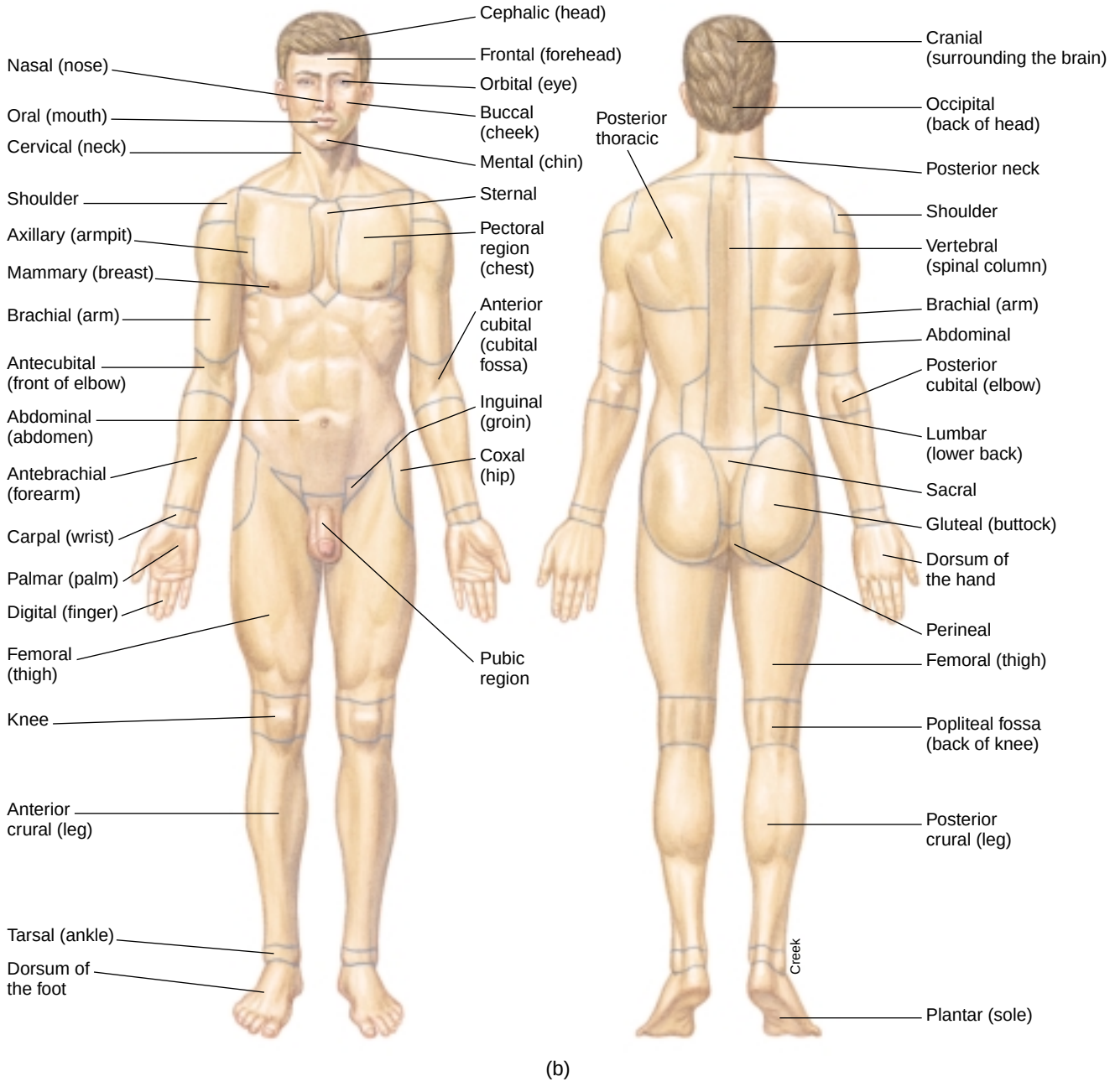

FIGURE 2.14 Body regions. (*a*) An anterior view and (*b*) a posterior view.

are the *head*, *neck*, *trunk*, *upper extremity*, and *lower extremity* (fig. 2.14). The trunk is frequently divided into the thorax, abdomen, and pelvis.

Head

The head is divided into a facial region, which includes the eyes, nose, and mouth, and a cranial region, or cranium *(kra'ne-um)*, which covers and supports the brain. The identifying names for specific surface regions of the face are based on associated organs—for example, the orbital (eye), nasal (nose), oral (mouth), and auricular (ear) regions—or underlying bones—for example, the frontal, temporal parietal, zygomatic, and occipital regions.

Neck

The neck, referred to as the cervical region, supports the head and permits it to move. As with the head, detailed subdivisions of the neck can be identified. Additional information concerning the neck region can be found in chapter 10.

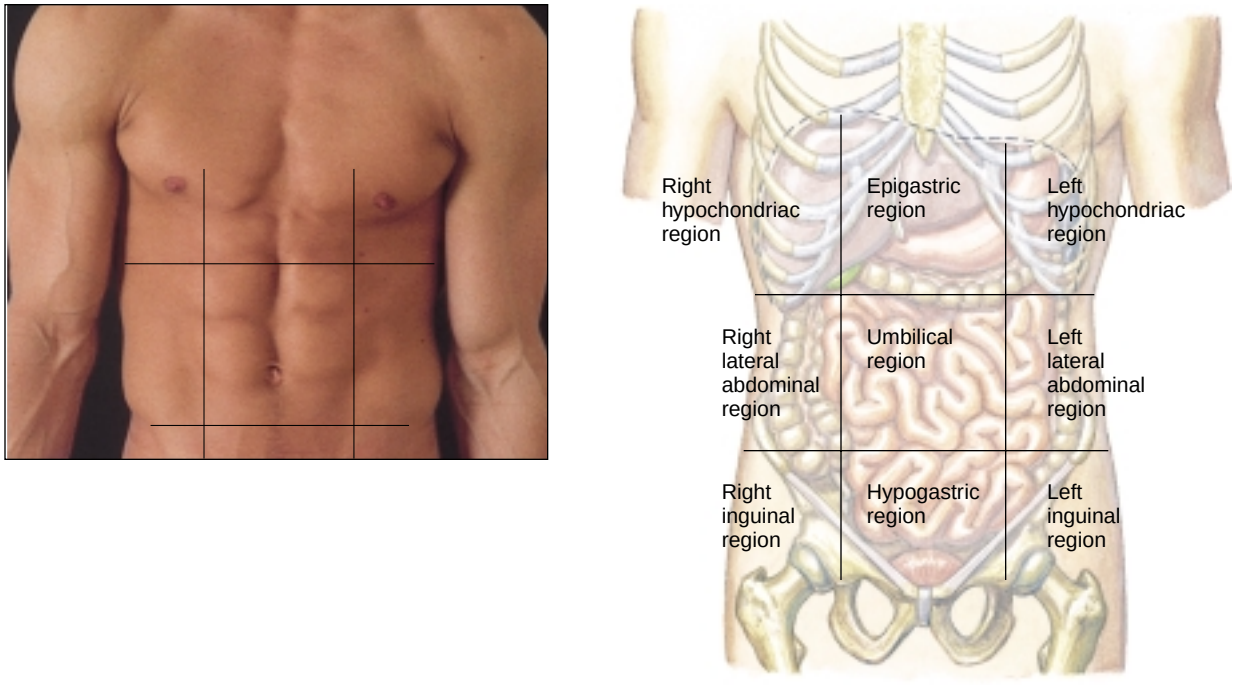

FIGURE 2.15 The abdomen is frequently subdivided into nine regions. The upper vertical planes are positioned lateral to the rectus abdominis muscles, the upper horizontal plane is positioned at the level of the rib cage, and the lower horizontal plane is even with the upper border of the hipbones.

Trunk

The **trunk**, or *torso*, is the portion of the body to which the neck and upper and lower extremities attach. It includes the thorax, abdomen, and pelvic region.

Thorax

The thorax *(thor'aks)*, or **thoracic** *(thŏ-ras'ik)* **region**, is commonly referred to as the chest. The **mammary region** of the thorax surrounds the nipple and in sexually mature females is enlarged as the breast. Between the mammary regions is the **sternal region**. The armpit is called the **axillary fossa**, or simply the **axilla**, and the surrounding area, the **axillary region**. The **vertebral region** extends the length of the back, following the vertebral column.

The heart and lungs are located within the thoracic cavity. Easily identified surface landmarks are helpful in assessing the condition of these organs. A physician must know, for example, where the valves of the heart can best be detected and where to listen for respiratory sounds. The axilla becomes important when examining for infected lymph nodes. When fitting a patient for crutches, a physician will instruct the patient to avoid supporting the weight of the body on the axillary region because of the possibility of damaging the underlying nerves and vessels.

thorax: L. *thorax*, chest

mammary: L. *mamma*, breast

axillary: L. *axilla*, armpit

Abdomen

The abdomen (*ab'dŏ-men*) is located below the thorax. Centered on the front of the abdomen, the **umbilicus (navel)** is an obvious landmark. The abdomen has been divided into nine regions to describe the location of internal organs. The subdivisions of the abdomen are diagrammed in figure 2.15 and the internal organs located within these regions are identified in table 2.4. Subdividing the abdomen into four quadrants (fig. 2.16) is a common clinical practice for locating the sites of pains, tumors, or other abnormalities.

Pelvic Region

The pelvic region forms the lower portion of the trunk. Within the pelvic region is the **pubic area**, which is covered with pubic hair in sexually mature individuals. The **perineum** (*per"ĭ-ne'um*) (fig. 2.17) is the region containing the external sex organs and the anal opening. The center of the back side of the abdomen, commonly called the small of the back, is the **lumbar region**. The **sacral region** is located further down, at the point where the vertebral column terminates. The large hip muscles form the **buttock**, or **gluteal region**. This region is a common injection site for hypodermic needles.

Upper Extremity

The **upper extremity** is anatomically divided into the **shoulder**, **brachium** (*bra'ke-um*) (arm), **antebrachium** (forearm), and **manus** (hand) (see fig. 2.14). The shoulder is the region between

TABLE 2.4 Regions of the Abdomen and Pelvis

Region	Location	Internal Organs
Right hypochondriac	Right, upper one-third of abdomen	Gallbladder; portions of liver and right kidney
Epigastric	Upper, central one-third of abdomen	Portions of liver, stomach, pancreas, and duodenum
Left hypochondriac	Left, upper one-third of abdomen	Spleen; splenic flexure of colon; portions of left kidney and small intestine
Right lateral	Right, lateral one-third of abdomen	Cecum; ascending colon; hepatic flexure; portions of right kidney and small intestine
Umbilical	Center of abdomen	Jejunum; ileum; portions of duodenum, colon, kidneys, and major abdominal vessels
Left lateral	Left, lateral one-third of abdomen	Descending colon; portions of left kidney and small intestine
Right inguinal	Right, lower one-third of abdomen	Appendix; portions of cecum and small intestine
Pubic (hypogastric)	Lower, center one-third of abdomen	Urinary bladder; portions of small intestine and sigmoid colon
Left inguinal	Left, lower one-third of abdomen	Portions of small intestine, descending colon, and sigmoid colon

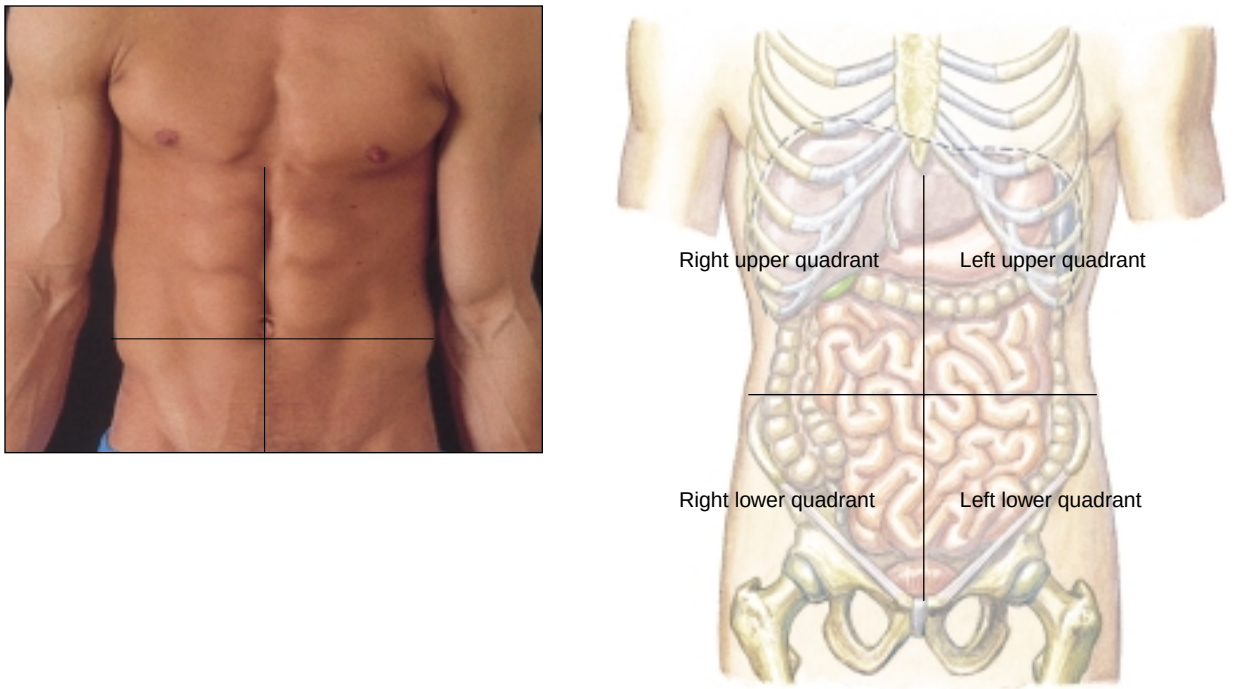

FIGURE 2.16 A clinical subdivision of the abdomen into four quadrants by a median plane and a transverse plane through the umbilicus.

the pectoral girdle and the brachium that contains the shoulder joint. The shoulder is also referred to as the **omos**, or **deltoid region**. The **cubital region** is the area between the arm and forearm that contains the elbow joint. The **cubital fossa** is the depressed anterior portion of the cubital region. It is an important site for intravenous injections or the withdrawal of blood.

The manus has three principal divisions: the **carpus**, containing the carpal bones (see fig. 7.8); the **metacarpus**, containing the metacarpal bones; and the five **digits** (commonly called fingers), containing the phalanges. The front of the hand is referred to as the **palmar region** (palm) and the back of the hand is called the **dorsum of the hand**.

cubital: L. *cubitis*, elbow

Lower Extremity

The **lower extremity** consists of the **hip**, **thigh**, **knee**, **leg**, and **pes** (foot). The thigh is commonly called the **upper leg**, or **femoral region**. The knee has two surfaces: the front surface is

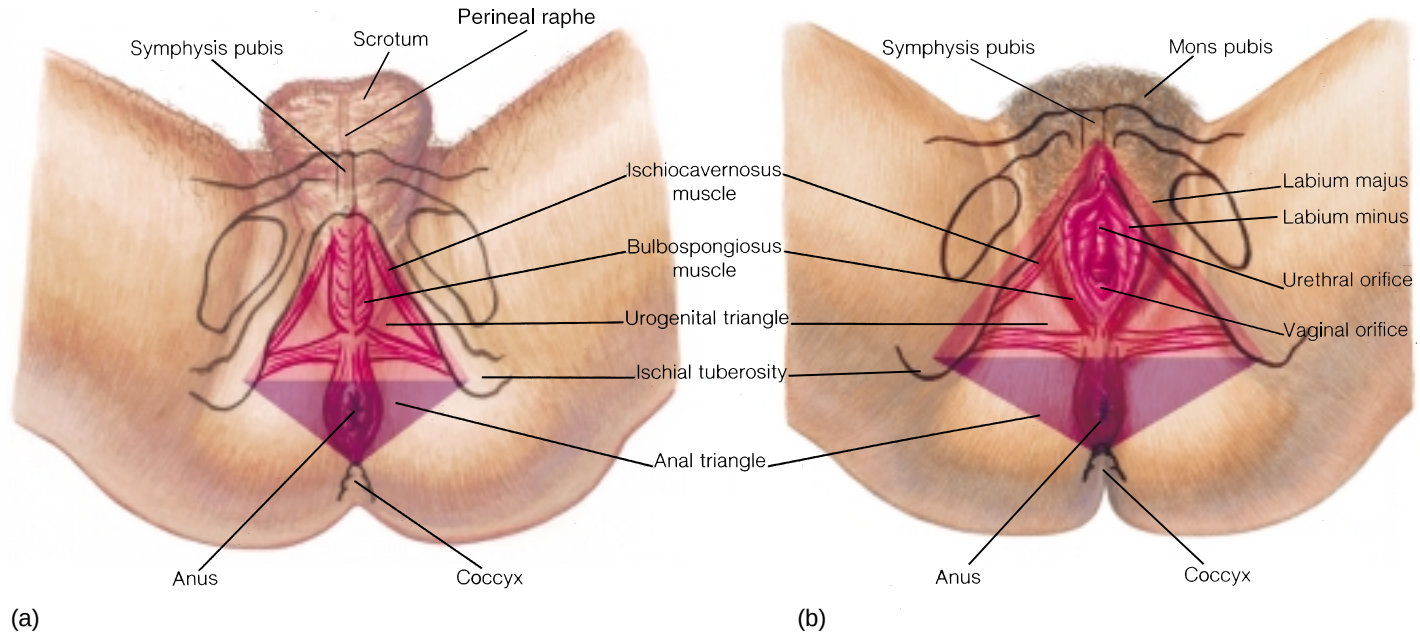

FIGURE 2.17 A superficial view of the perineum of (*a*) a male and (*b*) a female. The perineal region can be divided into a urogenital triangle (anteriorly) and an anal triangle (posteriorly).

the **patellar region**, or kneecap; the back of the knee is called the **popliteal** (*pop"lĭ-te'al*) **fossa**. The leg has anterior and posterior **crural regions** (see fig. 2.14). The *shin* is a prominent bony ridge extending longitudinally along the anterior crural region, and the *calf* is the thickened muscular mass of the posterior crural region.

The pes has three principal divisions: the **tarsus**, containing the tarsal bones (see fig. 7.19); the **metatarsus**, containing the metatarsal bones; and the five **digits** (commonly called toes), containing the phalanges. The **ankle** is the junction between the leg and the foot. The **heel** is the back of the foot, and the **sole** of the foot is referred to as the **plantar surface**. The **dorsum of the foot** is the top surface.

Knowledge Check

12. Using yourself as a model, identify the various body regions depicted in figure 2.14. Which of these regions have surface landmarks that help distinguish their boundaries?
13. In which region of the body are intravenous injections given?
14. Distinguish the pubic area and perineum within the pelvic region.
15. Identify the joint between the following regions: the brachium and antebrachium, the pectoral girdle and brachium, the leg and foot, the antebrachium and hand, and the thigh and leg.
16. Explain how knowledge of the body regions is applied in a clinical setting.

BODY CAVITIES AND MEMBRANES

For functional and protective purposes, the viscera are compartmentalized and supported in specific body cavities by connective and epithelial membranes.

Objective 13 Identify the various body cavities and the organs found in each.

Objective 14 Discuss the types and functions of the various body membranes.

Body Cavities

Body cavities are confined spaces within the body. They contain organs that are protected, compartmentalized, and supported by associated membranes. There are two principal body cavities: the **posterior (dorsal) body cavity** and the larger **anterior (ventral) body cavity**. The posterior body cavity contains the brain and the spinal cord. During development, the anterior cavity forms from a cavity within the trunk called the **coelom** (*se'lom*). The coelom is lined with a membrane that secretes a lubricating fluid. As development progresses, the coelom is partitioned by the muscular **diaphragm** into an upper **thoracic cavity**, or chest cavity, and a lower **abdominopelvic cavity** (figs. 2.18 and 2.19). Organs within the coelom are collectively called **viscera** (*vis'er-ă*), or **visceral organs** (fig. 2.20). Within the thoracic cavity are two **pleural** (*ploor'al*) **cavities** surrounding the right and left lungs

popliteal: L. *poples*, ham (hamstring muscles) of the knee

coelom: Gk. *koiloma*, a cavity

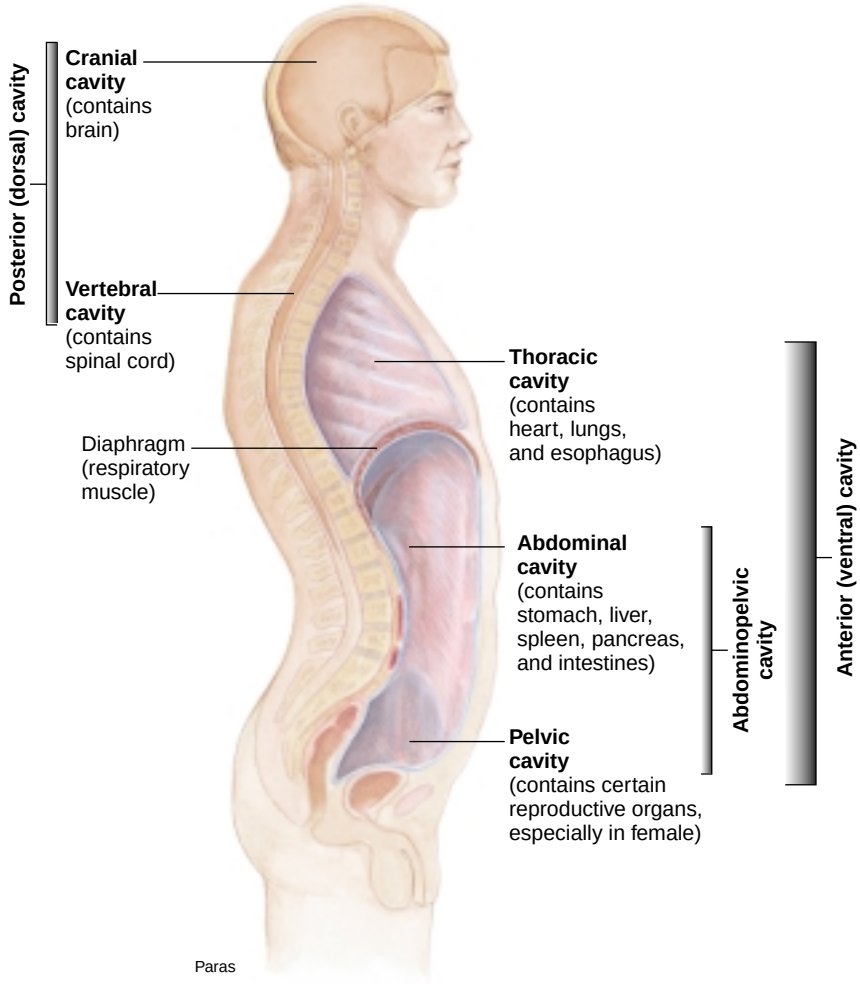

FIGURE 2.18 A midsagittal (median) section showing the body cavities and principal contents.

and a **pericardial** (*per"ĭ-kar'de-al*) **cavity** surrounding the heart (fig. 2.21). The area between the two pleural cavities is known as the **mediastinum** (*me"de-ă-sti'num*).

The abdominopelvic cavity consists of an upper **abdominal cavity** and a lower **pelvic cavity**. The abdominal cavity contains the stomach, small intestine, large intestine, liver, gallbladder, pancreas, spleen, and kidneys. The pelvic cavity is occupied by the terminal portion of the large intestine, the urinary bladder, and certain reproductive organs (uterus, uterine tubes, and ovaries in the female; seminal vesicles and prostate in the male).

A summary of the principal body cavities is presented in figure 2.22.

Body cavities serve to confine organs and systems that have related functions. The major portion of the nervous system occupies the posterior cavity; the principal organs of the respiratory and circulatory systems are in the thoracic cavity; the primary organs of digestion are in the abdominal cavity; and the reproductive organs are in the pelvic cavity. Not only do these cavities house and support various body organs, they also effectively compartmentalize them so that infections and diseases cannot spread from one compartment to another. For example, pleurisy of one lung membrane does not usually spread to the other, and an injury to the thoracic cavity will usually result in the collapse of only one lung rather than both.

In addition to the large anterior and posterior cavities, there are several smaller cavities and spaces within the head. The **oral cavity** functions primarily in digestion and secondarily in respiration. It contains the teeth and tongue. The **nasal cavity**, which is part of the respiratory system, has two chambers created by a nasal septum. There are two **orbits**, each of which houses an eyeball and its associated muscles, vessels, and nerves. Likewise, there are two **middle-ear cavities** containing the auditory ossicles (ear bones). The location of the cavities and spaces within the head is shown in figure 2.23.

orbital: L. *orbis*, circle

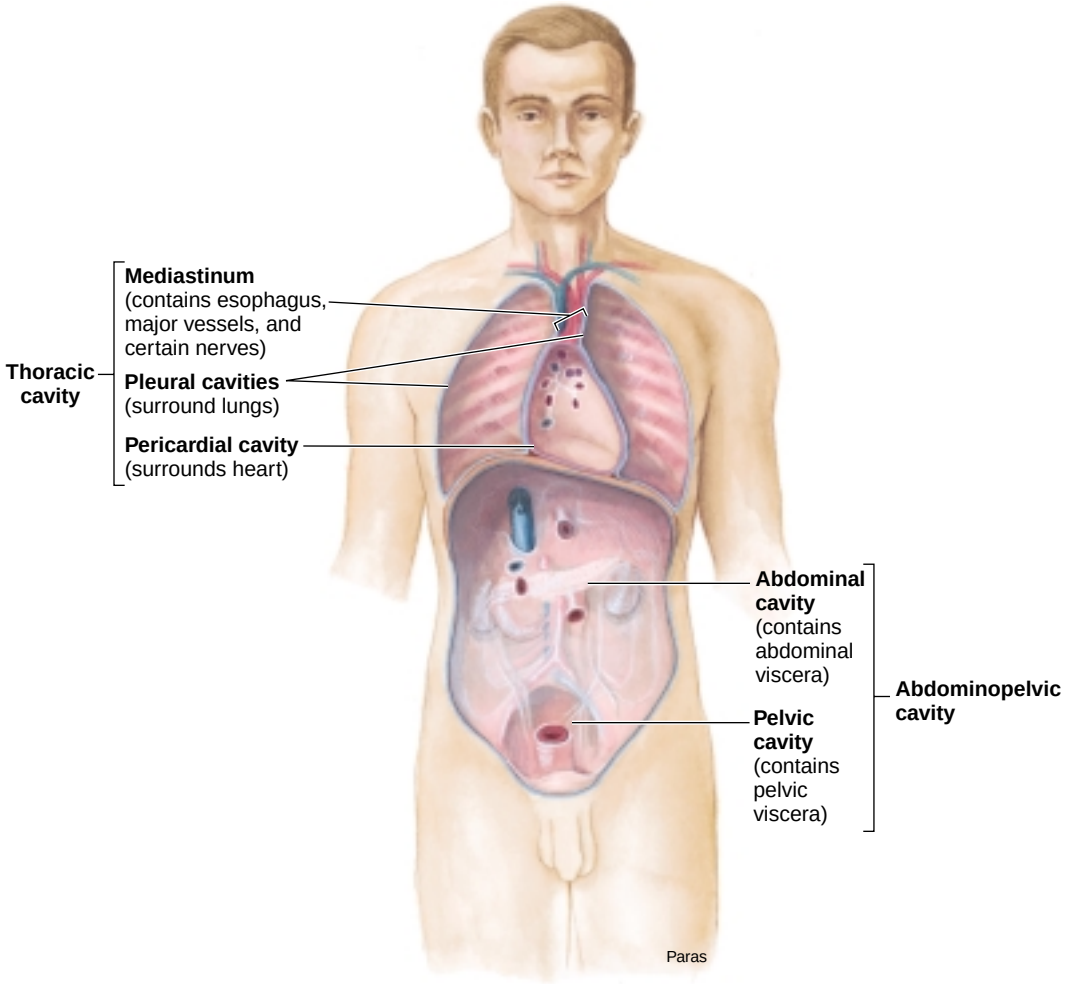

FIGURE 2.19 An anterior view showing the cavities of the trunk.

Body Membranes

Body membranes are composed of thin layers of connective and epithelial tissue that cover, separate, and support visceral organs and line body cavities. There are two basic types of body membranes: **mucous** *(myoo'kus)* **membranes** and **serous** *(se'rus)* **membranes**.

Mucous membranes secrete a thick, sticky fluid called *mucus*. Mucus generally lubricates or protects the associated organs where it is secreted. Mucous membranes line various cavities and tubes that enter or exit the body, such as the oral and nasal cavities and the tubes of the respiratory, reproductive, urinary, and digestive systems.

Serous membranes line the thoracic and abdominopelvic cavities and cover visceral organs, secreting a watery lubricant called *serous fluid*. **Pleurae** are serous membranes associated with the lungs. Each pleura (pleura of right lung and pleura of left lung) has two parts. The **visceral pleura** adheres to the outer surface of the lung, whereas the **parietal** (*pă-ri'ĕ-tal*) **pleura** lines the thoracic walls and the thoracic surface of the diaphragm. The moistened space between the two pleurae is known as the **pleural cavity** (fig. 2.21).

Pericardial membranes are the serous membranes covering the heart. A thin **visceral pericardium** covers the surface of the heart, and a thicker **parietal pericardium** surrounds the heart. The space between these two membranes is called the **pericardial cavity**.

Serous membranes of the abdominal cavity are called **peritoneal** (*per"ĭ-tŏ-ne'al*) **membranes**. The **parietal peritoneum** lines the abdominal wall, and the **visceral peritoneum** covers the abdominal viscera. The **peritoneal cavity** is the potential space within the abdominopelvic cavity between the parietal

peritoneum: Gk. *peritonaion*, stretched over

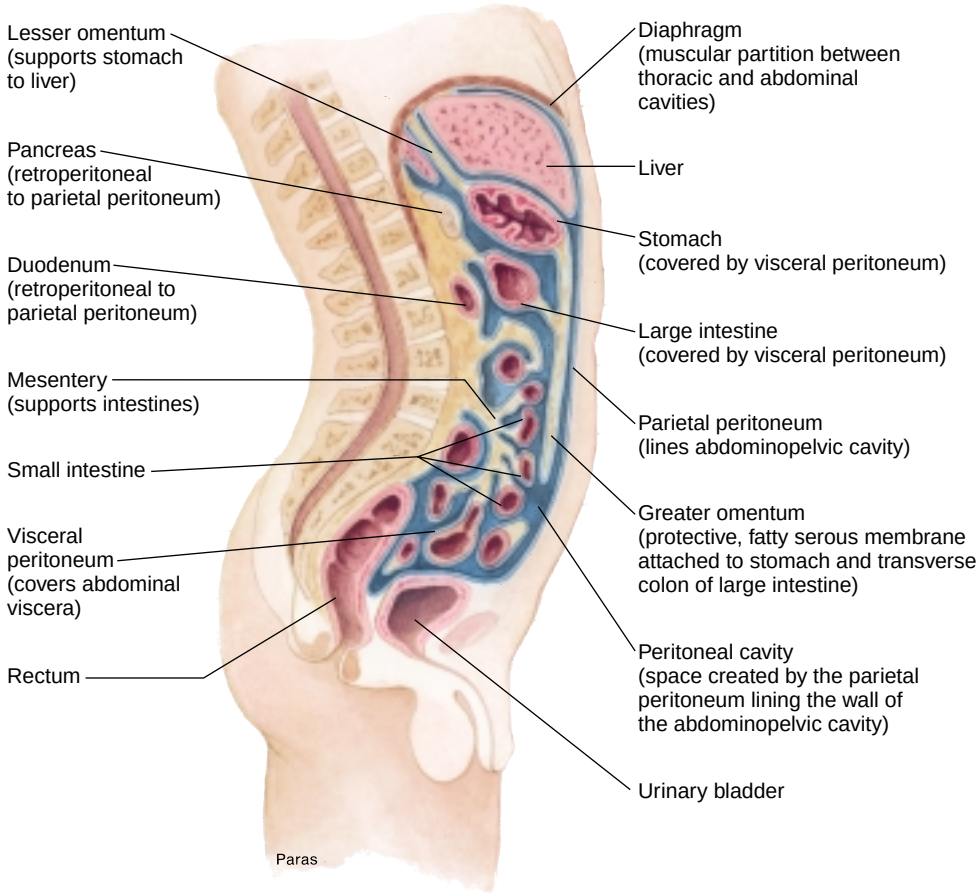

FIGURE 2.20 Visceral organs of the abdominopelvic cavity and the associated serous membranes.

and visceral peritoneal membranes. The *lesser omentum* and the *greater omentum* are folds of the peritoneum that extend from the stomach. They store fat and cushion and protect the abdominal viscera. Certain organs, such as the kidneys, adrenal glands, and the medial portion of the pancreas, which are within the abdominopelvic cavity, are positioned behind the parietal peritoneum, and are therefore said to be *retroperitoneal*. **Mesenteries** (*mes'en-ter"ēz*) are double folds of peritoneum that connect the parietal peritoneum to the visceral peritoneum (see figs. 2.20 and 18.3).

Knowledge Check

17. Describe the divisions and boundaries of the anterior body cavity and list the major organs contained within each division.
18. Distinguish between mucous and serous membranes and list the specific serous membranes of the thoracic and abdominopelvic cavities.
19. Explain the importance of separate and distinct body cavities.

Clinical Case Study Answer

Normally, the thoracic cavity is effectively separated from the abdominopelvic cavity by the diaphragm, peritoneum, and pleura. The phenomenon of peritoneal lavage fluid draining out of a tube properly placed in the chest can be explained only by the presence of a defect in the diaphragm. The defect in our patient is likely a traumatic rupture or laceration of the diaphragm that was caused by a sharp blow to the abdomen. The blow would have produced sudden upward pressure against the diaphragm, causing it to rupture. The absence of bile, blood, etc., in peritoneal lavage fluid does not guarantee the absence of trauma to organs such as the duodenum and pancreas. These organs are not located within the peritoneal cavity; rather they are retroperitoneal, or fully posterior to the peritoneal membrane. This keeps blood or leaked enzymes from these organs out of the peritoneal space and away from lavage fluid. Other signs must therefore be relied upon, and a high index of suspicion maintained, so as not to overlook injury to these organs. Evidence of injury to any of the intraabdominal organs, or the presence of diaphragmatic rupture, calls for emergency laparotomy (abdominal incision) to repair the structures involved.

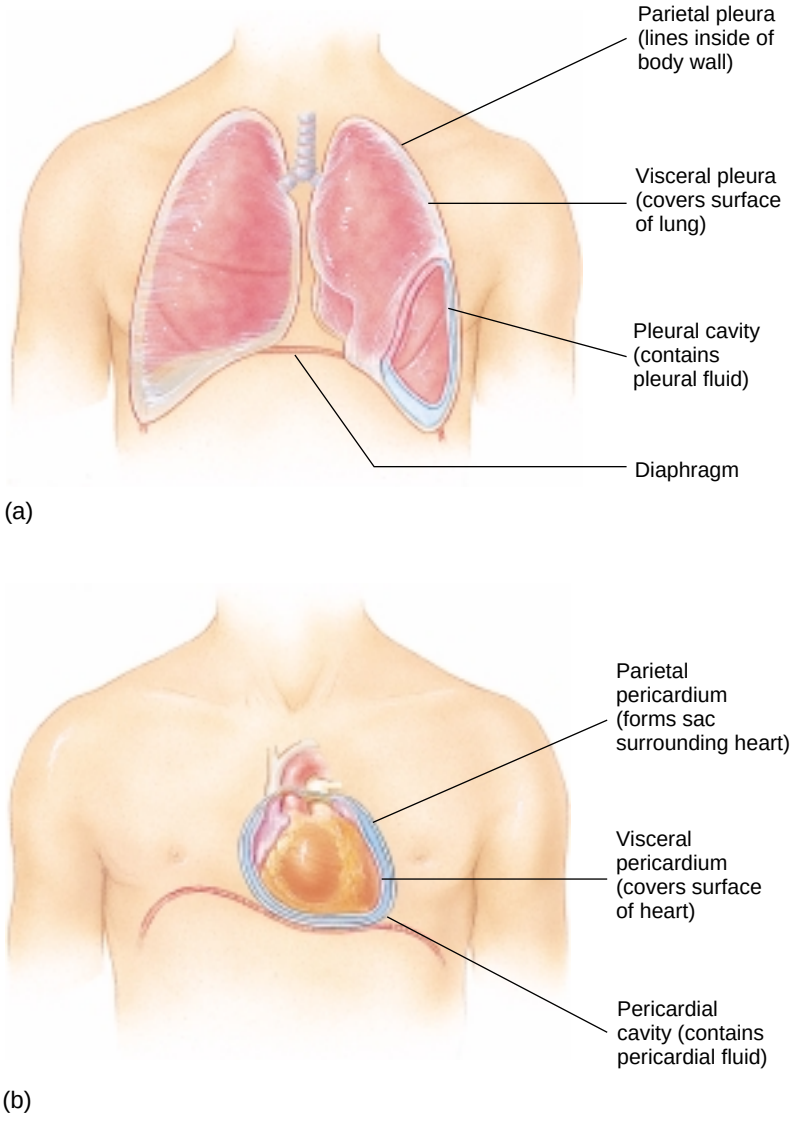

FIGURE 2.21 Serous membranes of the thorax (*a*) surrounding the lungs and (*b*) surrounding the heart.

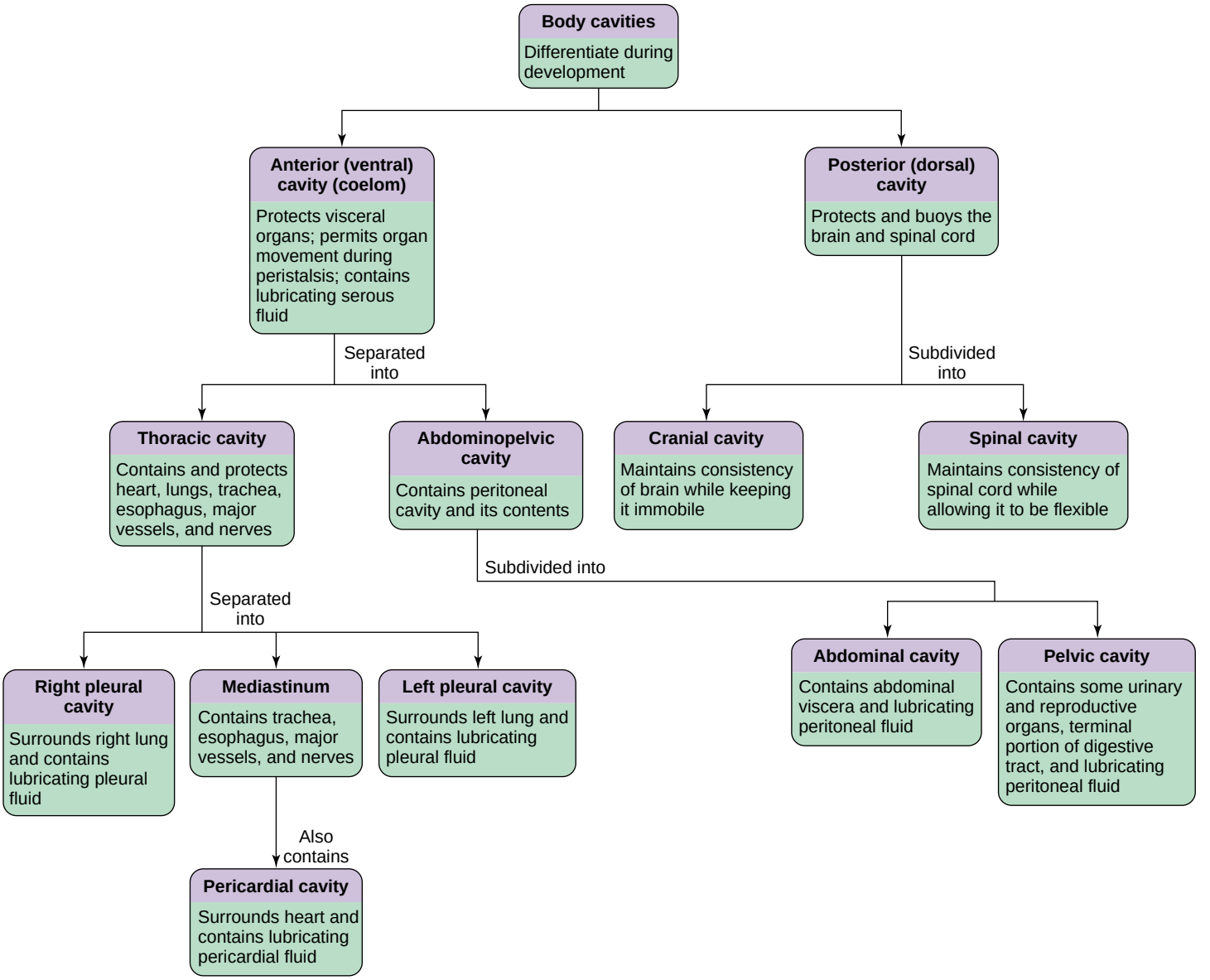

FIGURE 2.22 Organization of body cavities.

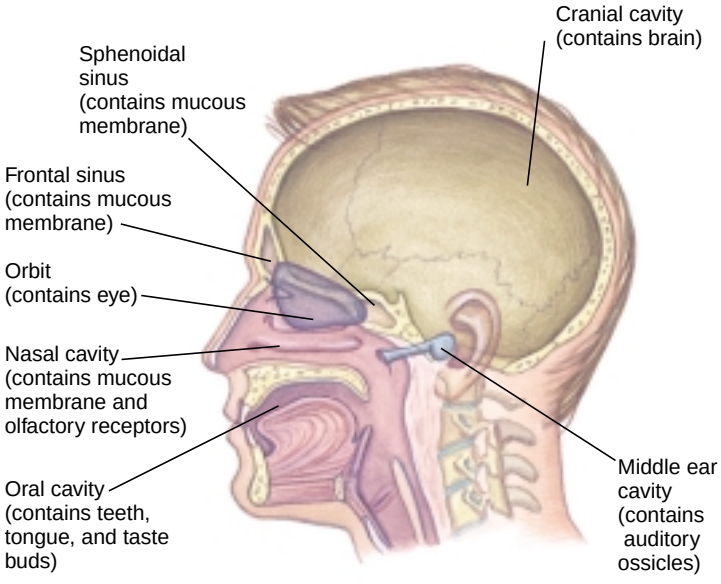

FIGURE 2.23 Cavities and spaces within the head.

Chapter Summary

Classification and Characteristics of Humans (pp. 00)

1. Our scientific name, *Homo sapiens*, means "man the intelligent," and our intelligence is our most distinguishing feature.
2. Humans belong to the phylum Chordata because of the presence of a notochord, a dorsal hollow nerve cord, and pharyngeal pouches during the embryonic stage of human development.
3. Humans are mammals, and as such have mammalian characteristics. These include hair, mammary glands, three auditory ossicles, heterodontia, a placenta, a muscular diaphragm, and a four-chambered heart with a left aortic arch.
4. Humans are also classified within the order Primates. Primates have prehensile hands, digits modified for grasping, and well-developed brains.
5. Humans are the sole members of the family Hominidae.
6. Some of the characteristics of humans are a large, well-developed brain; bipedal locomotion; an opposable thumb; well-developed vocal structures; and stereoscopic vision.

Body Organization (pp. 00)

1. Cells are the fundamental structural and functional components of life.
2. Tissues are aggregations of similar cells that perform specific functions.
3. An organ is a structure consisting of two or more tissues that performs a specific function.
4. A body system is composed of a group of organs that function together.

Anatomical Nomenclature (p. 00)

1. Most anatomical terms are derived from Greek or Latin words that provide clues to the meaning of the terms.
2. Familiarity with the basic prefixes and suffixes facilitates learning and remembering anatomical terminology.
3. Anatomy is a foundation science for all of the medical and paramedical fields.

Planes of Reference and Descriptive Terminology (pp. 00)

1. The body or organs of the body may be sectioned according to planes of reference. These include a midsagittal plane that runs vertically through a structure, dividing it into right and left halves; a sagittal plane that runs vertically through a structure, dividing it into right and left portions; a coronal (frontal) plane that runs vertically through a structure, dividing it into anterior (front) and posterior (back) portions; and a transverse (cross-sectional) plane that runs horizontally through a structure, dividing it into upper and lower portions.
2. In the anatomical position, the subject is standing with feet parallel, eyes directed forward, and arms at the sides of the body with palms turned forward and fingers pointing downward.
3. Directional terms are used to describe the location of one body part with respect to another part in anatomical position.
4. Clinical procedures include observation (visual inspection), palpation (feeling with firm pressure), percussion (detecting resonating vibrations), auscultation (listening to organ sounds), and reflex-response testing (determining involuntary movements).

Body Regions (pp. 00)

1. The head is divided into a facial region, which includes the eyes, nose, and mouth, and a cranial region, which covers and supports the brain.
2. The neck is called the cervical region and functions to support the head and permit movement.
3. The front of the thorax is subdivided into two mammary regions and one sternal region.
4. On either side of the thorax is an axillary fossa and a lateral pectoral region.
5. The abdomen may be divided into nine anatomical regions or four quadrants.
6. Regional names pertaining to the upper extremity include the shoulder, brachium, antebrachium, and manus.
7. Regional names pertaining to the lower extremity include the hip, thigh, leg, and foot.

Body Cavities and Membranes (pp. 00)

1. The posterior cavity, which encompasses the cranial and spinal cavities, encloses and protects the brain and spinal cord—the central nervous system.
2. The anterior cavity, which encompasses the thoracic and abdominopelvic cavities, contains the visceral organs.
3. Other body cavities include the oral, nasal, and middle-ear cavities.
4. The body has two principal types of membranes: mucous membranes, which secrete protective mucus, and serous membranes, which line the ventral cavities and cover visceral organs. Serous membranes secrete a lubricating serous fluid.
5. Serous membranes may be categorized as pleural membranes (associated with the lungs), pericardial membranes (associated with the heart), or peritoneal membranes (associated with the abdominal viscera).

Review Activities

Objective Questions

1. Which of the following is *not* a principal chordate characteristic?
   (a) a dorsal hollow nerve cord
   (b) a distinct head, thorax, and abdomen
   (c) a notochord
   (d) pharyngeal pouches
2. Prehensile hands, digits modified for grasping, and large, well-developed brains are structural characteristics of the grouping of animals referred to as
   (a) primates. (c) mammals.
   (b) vertebrates. (d) chordates.
3. Layers or aggregations of similar cells that perform specific functions are called
   (a) organelles. (c) organs.
   (b) tissues. (d) glands.
4. Filtration and maintenance of the volume and the chemical composition of the blood are functions of
   (a) the urinary system.
   (b) the lymphatic system.
   (c) the circulatory system.
   (d) the endocrine system.
5. The cubital fossa is located in
   (a) the thorax.
   (b) the upper extremity.
   (c) the abdomen.
   (d) the lower extremity.
6. Because it is composed of more than one tissue type, the skin is considered
   (a) a composite tissue.
   (b) a system.
   (c) an organ.
   (d) an organism.
7. Which of the following is *not* a reference plane?
   (a) coronal (c) vertical
   (b) transverse (d) sagittal
8. The external genitalia (reproductive organs) are located in
   (a) the popliteal fossa.
   (b) the perineum.
   (c) the hypogastric region.
   (d) the epigastric region.
9. The region of the thoracic cavity between the two pleural cavities is called
   (a) the midventral space.
   (b) the mediastinum.
   (c) the ventral cavity.
   (d) the median cavity.
10. The abdominal region superior to the umbilical region that contains most of the stomach is
    (a) the hypochondriac region.
    (b) the epigastric region.
    (c) the diaphragmatic region.
    (d) the inguinal region.
11. Regarding serous membranes, which of the following word pairs is *incorrect?*
    (a) visceral pleura/lung
    (b) parietal peritoneum/body wall
    (c) mesentery/heart
    (d) parietal pleura/body wall
    (e) visceral peritoneum/intestines
12. The plane of reference that divides the body into anterior and posterior portions is
    (a) sagittal. (c) coronal.
    (b) transverse. (d) cross-sectional.
13. In the anatomical position,
    (a) the arms are extended away from the body.
    (b) the palms of the hands face posteriorly.
    (c) the body is erect and the palms face anteriorly.
    (d) the body is in a fetal position.
14. Listening to sounds that functioning visceral organs make is called
    (a) percussion. (c) audiotation.
    (b) palpation. (d) auscultation.

Essay Questions

1. Discuss the characteristics an animal must possess to be classified as a chordate; a mammal; a human.
2. Describe the relationship of the notochord to the vertebral column, the pharyngeal pouches to the ear, and the dorsal hollow nerve cord to the central nervous system.
3. Which grouping of animals are we most closely related to? What anatomical characteristics do we have in common with them?
4. List the anatomical characteristics that distinguish humans.
5. Identify the levels of complexity that characterize the human body.
6. Outline the systems of the body and identify the major organs that compose each system.
7. What is meant by anatomical position? Why is the anatomical position important in studying anatomy?
8. Define the terms *palpation*, *percussion*, and *auscultation*.
9. Which major region of the body contains each of the following structures or minor regions:
   (a) scapular region,
   (b) brachium,
   (c) popliteal fossa,
   (d) lumbar region,
   (e) cubital fossa,
   (f) hypochondriac region,
   (g) perineum,
   (h) axillary fossa.

10. List the cavities and spaces found within the head and explain the functions of each.
11. Diagram the thoracic cavity showing the relative position of the pericardial cavity, pleural cavities, and mediastinum.
12. What is a serous membrane? Explain how the names of the serous membranes differ in accordance with each body cavity.

Critical-Thinking Questions

1. Smooth muscle is a tissue type. Using examples, discuss the level of body organization "below" smooth muscle tissue and the level of body organization "above" smooth muscle tissue. Which of these levels would be studied as microscopic anatomy and which would be studied as gross anatomy?
2. Arteries transport blood away from the heart and veins transport blood toward the heart. Using the terms *anterior*, *proximal*, *distal*, *medial*, and *lateral*, describe blood flow from the heart to the palm of the hand and right thumb and back to the heart. In answering this question, keep the anatomical position in mind. Also, be aware that adding an "ly" to these directional terms changes them from adjectives to adverbs.
3. Vital body organs are those that are essential for critical body functions. Examples are the heart in pumping blood, the liver in processing foods and breaking down worn blood cells, the kidneys in filtering blood, the lungs in exchanging respiratory gasses, and the brain in controlling and correlating body functions. Death of a person occurs when one or more of the vital body organs falters in its function. Explain why the reproductive organs are not considered vital body organs?
4. A 25-year-old man sustained trauma to the left lateral side of his rib cage following a rock-climbing accident. Upon arrival at the hospital emergency room, the ER doctor indicated that the extent of the injury could be determined only through the techniques of inspection, palpation, percussion, and auscultation. Describe how each of these techniques may be used to assess the condition of the thorax and thoracic organs.

Icon to come

Visit our Online Learning Center at http://www.mhhe.com/vdg.com for chapter-by-chapter quizzing, additional study resources, and related web links.