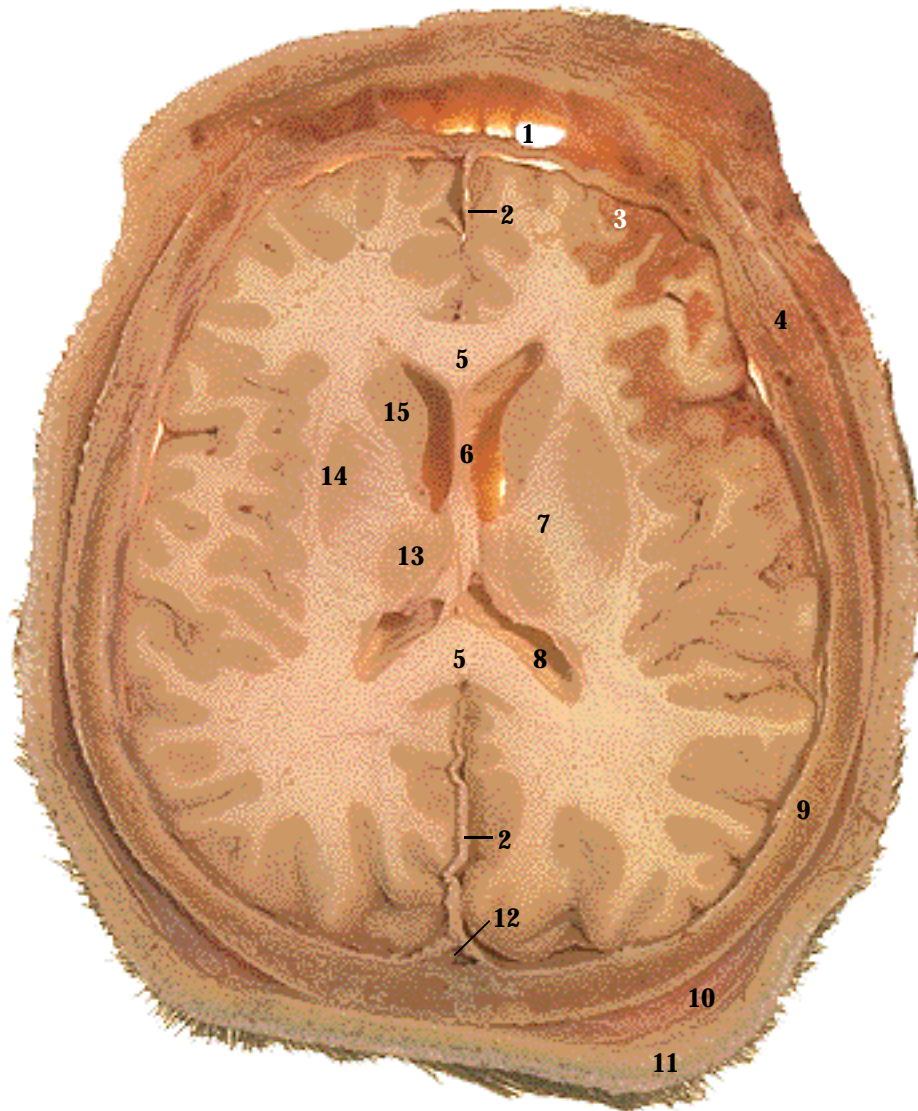

1. Frontal sinus
2. Falx cerebri
3. Cerebral cortex
4. Temporalis muscle
5. Corpus callosum
6. Septum pellucidum
7. Internal capsule
8. Lateral ventricle
9. Parietal bone
10. Hypodermis
11. Skin
12. Superior sagittal sinus
13. Thalamus
14. Lentiform nucleus
15. Caudate nucleus
16. Yellow bone marrow (MRI only)

Systemic Descriptions

Cardiovascular System

The superior sagittal sinus (12) drains blood from the brain (SST Figure 21-13).

Integumentary System

The skin (11) of the scalp covers the loose connective tissue of the hypodermis (10), which contains adipose tissue (SST Figure 5-1).

Muscular System

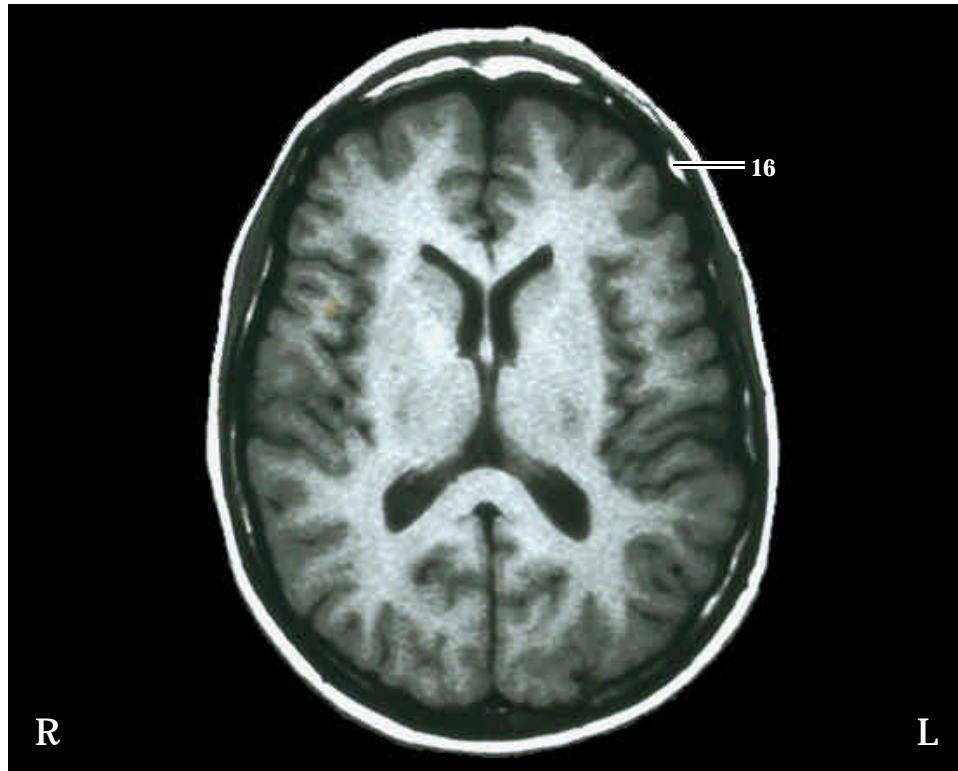The temporalis muscle (4) is a major muscle of mastication that attaches inferiorly to the mandible (SST Figure 11-8, A)

Nervous System

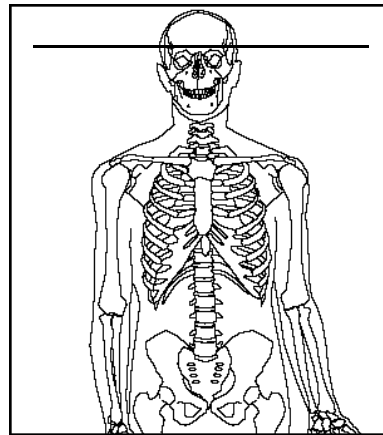
The cerebrum consists of gray matter and white matter. The gray matter forms the cortex (3) and nuclei (SST Figure 13-9). The caudate nucleus (15) and the lentiform nucleus (14) are basal ganglia (SST Figure 13-14). White matter nerve tracts are located between the gray matter. The internal capsule (7) consists of projection fibers that connect the cerebral cortex to the thalamus and brainstem (SST Figure 13-9). The corpus callosum consists of commissural fibers that connect the cerebral hemispheres to each other. The corpus callosum arches superiorly and only the anterior and posterior parts (5) are cut in this section (SST Figure 13-7, A). The lateral ventricles (8) are also arched structures cut into anterior and posterior parts (SST Figure 13-29). Note the septum pellucidum (6) separating the two lateral ventricles. The thalamus (13) is a yo-yo shaped collection of nuclei located near the midline of the brain (SST Figure 13-7, A and B). Extensions of the dura mater form the falx cerebri (2), which separates the cerebral hemispheres and helps to hold the brain in place.

Skeletal System

The frontal sinus (1) within the frontal bone (SST Figure 7-12). The frontal, parietal (9), and other braincase bones appear as a ring of bones when viewed in transverse section.

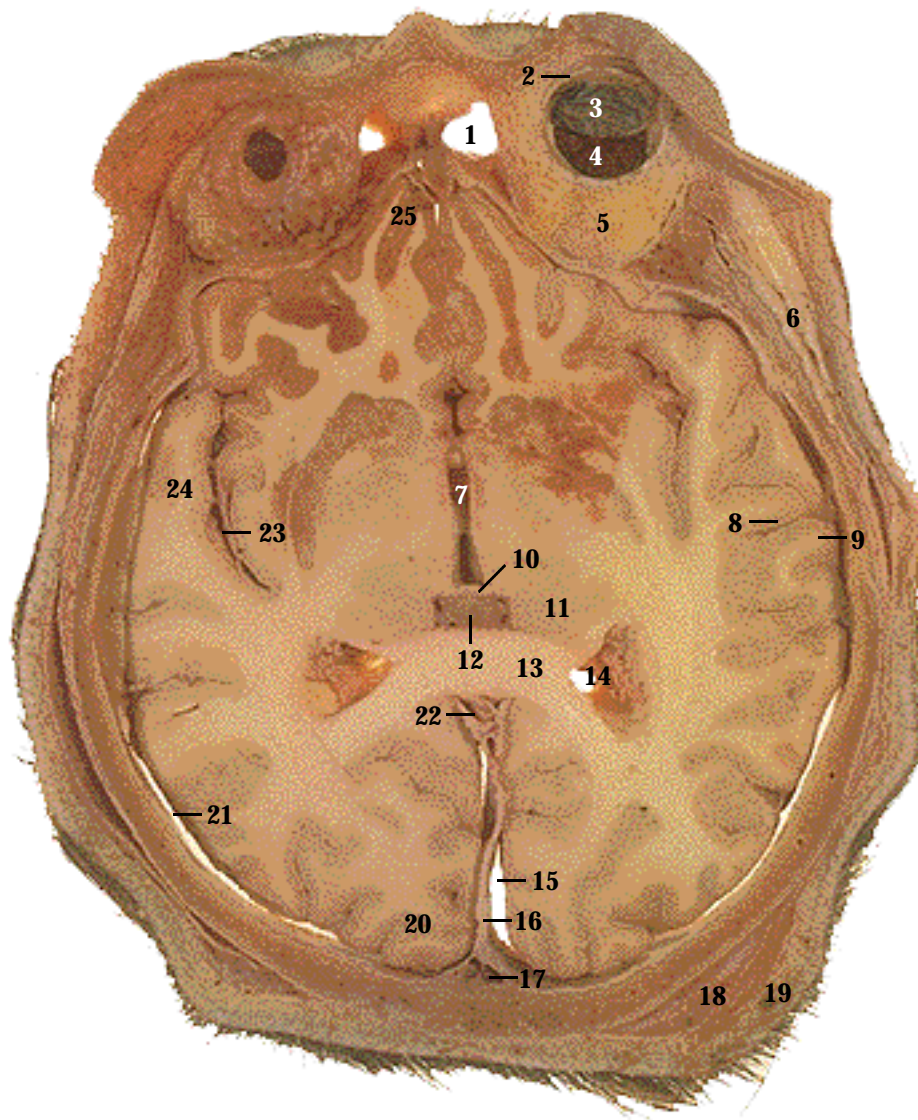


T1 MRI image. The skin and hypodermis appear as a white ring around the skull bones, which appear as a black ring. There is an unusual amount of conversion of red to yellow bone marrow. The fat content of the yellow bone marrow appears as white patches between the outer and inner layers of the bone (16) (Note that the frontal sinus is not visible in the MRI). The brain gray matter is dark gray and the brain white matter is gray. The lateral ventricles, which are filled with cerebrospinal fluid, appear black.



Level: Superior part of the braincase, 1 cm superior to the supraorbital margin.

SECTION 1



1. Frontal sinus
2. Sclera
3. Retina
4. Choroid
5. Orbital fat
6. Temporalis muscle
7. Third ventricle
8. Sulcus
9. Gyrus
10. Intermediate mass
11. Thalamus
12. Choroid plexus
13. Corpus callosum
14. Lateral ventricle
15. Longitudinal fissure
16. Falx cerebri
17. Superior sagittal sinus
18. Hypodermis
19. Skin
20. Occipital lobe
21. Subdural space
22. Inferior sagittal sinus
23. Lateral fissure
24. Temporal lobe
25. Frontal lobe

Systemic Descriptions

Cardiovascular System

The superior sagittal sinus (17) continues inferiorly from Section 1. The inferior sagittal sinus (22) is also cut at this level (SST Figure 21-13).

Integumentary System

The skin (19) of the scalp covers the loose connective tissue of the hypodermis (18), which contains adipose tissue (SST Figure 5-1).

Muscular System

The temporalis muscle (6) continues inferiorly.

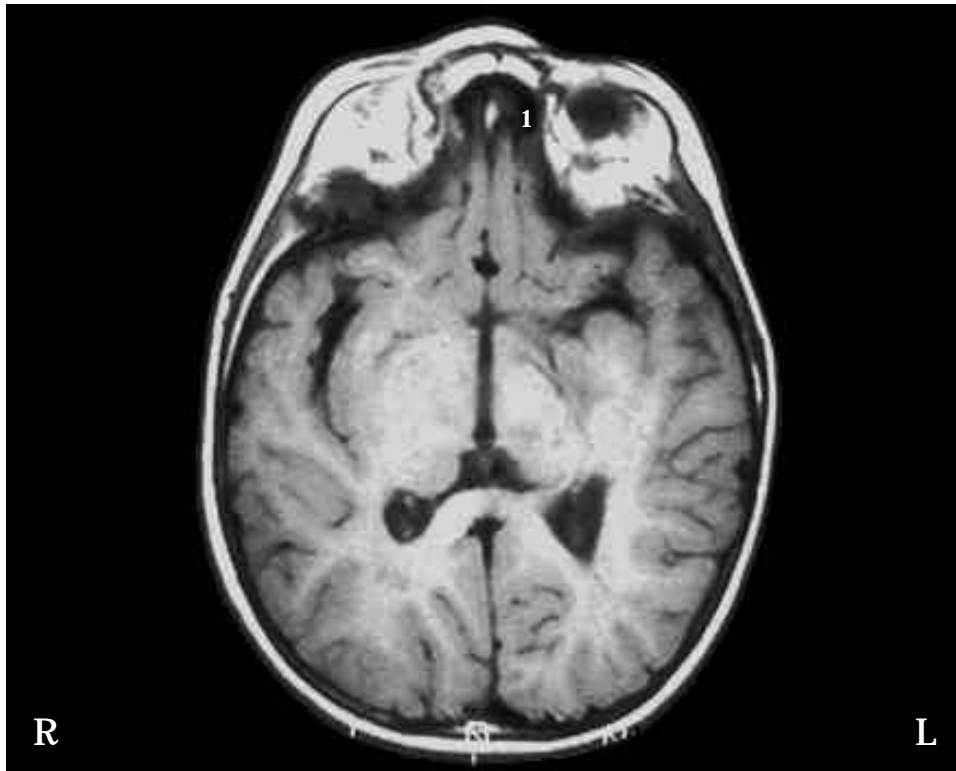
Nervous System

The longitudinal fissure (15) separates the two cerebral hemispheres. The lateral fissure (23) separates the temporal lobe (24) from the frontal lobe (25). The occipital lobe (20) is located posteriorly (SST Figure 13-8). The cerebral cortex consists of gyri (9) and sulci (8). The posterior parts of the corpus callosum (13) and lateral ventricles (14) are visible. At this level, the midline third ventricle (7) is also cut (SST Figure 13-29). A choroid plexus (12) in the third ventricle produces cerebrospinal fluid. The intermediate mass (10) connects the lobes of the thalamus (11) (SST Figure 13-7, B). An extension of the dura mater forms the falx cerebri (16). The subdural space (21) is deep to the dura mater (SST Figure 13-27, A).

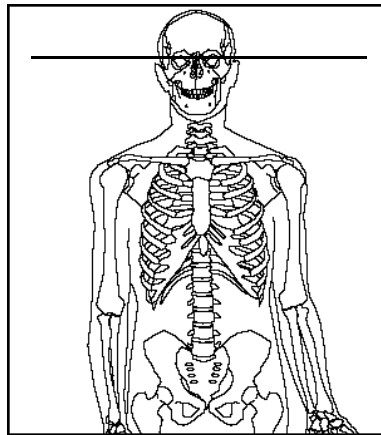
The sclera (2), choroid (4), and retina (3) form the wall of the eye (SST Figure 15-13), which is surrounded by orbital fat (5). The retina is folded over to show the choroid.

Skeletal System

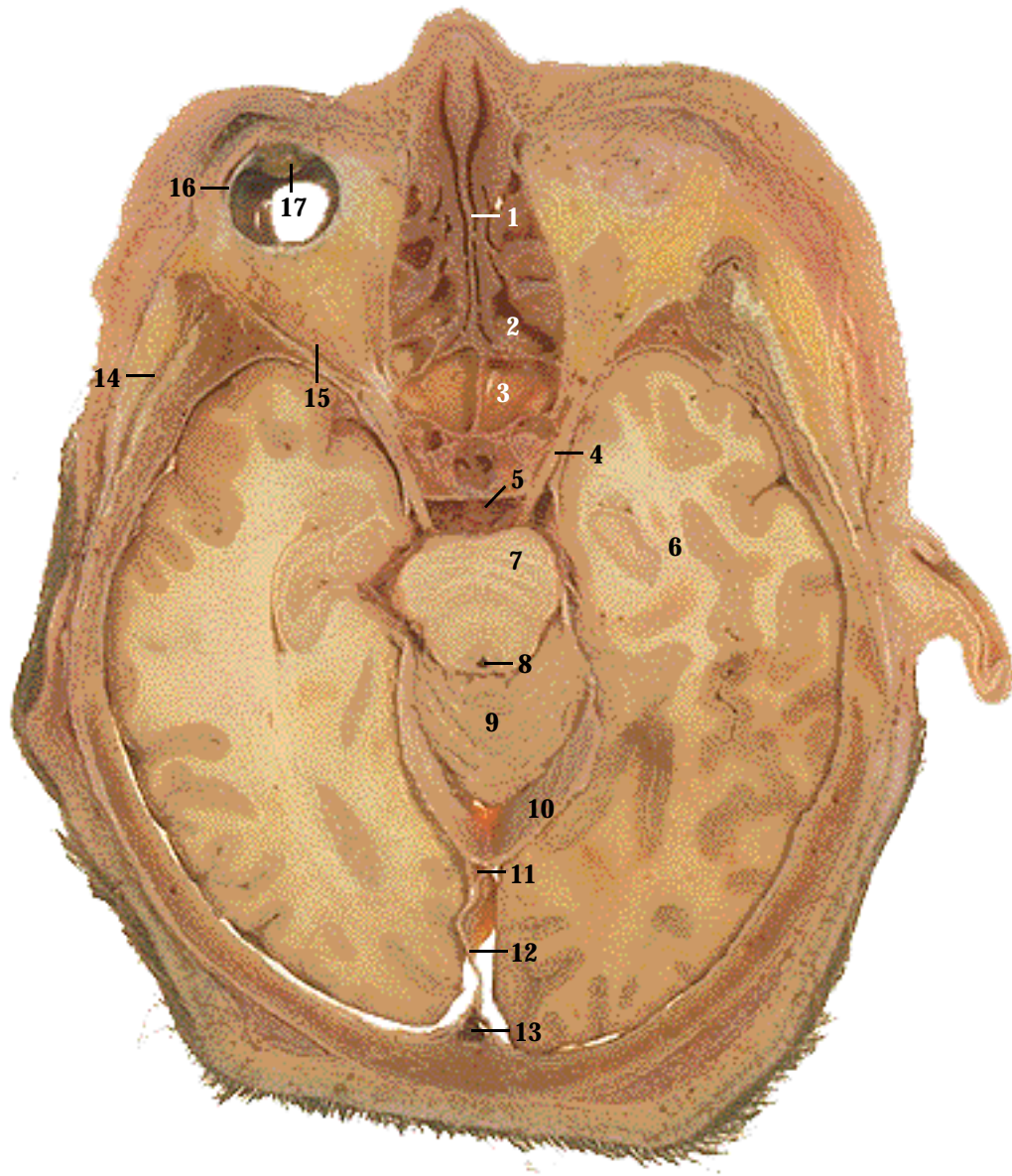
The frontal sinus (1) within the frontal bone (SST Figure 7-12).



T1 MRI image. The air-filled frontal sinus (1) appears black, and the orbital fat appears white. The midline third ventricle and the posterior horns of the lateral ventricles are dark gray to black. The posterior part of the corpus callosum, which connects the right and left cerebral hemispheres, is visible. Immediately posterior to the corpus callosum, the inferior sagittal sinus appears as a midline black density.



Level: Through the orbits.



1. Perpendicular plate of the ethmoid bone
2. Ethmoidal sinus
3. Sphenoidal sinus
4. Oculomotor nerve
5. Basilar artery
6. Cerebrum
7. Midbrain (cerebral peduncle)
8. Cerebral aqueduct
9. Cerebellum
10. Tentorium cerebelli
11. Straight sinus
12. Falx cerebri
13. Superior sagittal sinus
14. Temporalis muscle
15. Extrinsic eye muscle (lateral rectus)
16. Sclera
17. Lens
18. Optic nerve (MRI only)
19. Pituitary gland (MRI only)
20. Lateral ventricle (MRI only)

Systemic Descriptions

Cardiovascular System

The superior sagittal sinus (13) continues inferiorly. The inferior sagittal sinus from Section 2 becomes the straight sinus (11), which is in the junction of the tentorium cerebelli and falx cerebri (SST Figure 21-13). The basilar artery (5) is about to join the cerebral arterial circle (circle of Willis) (SST Figure 21-7, B)

Muscular System

The temporalis muscle (14) continues inferiorly. The extrinsic eye muscles (15) are responsible for moving the eyeball (SST Figure 15-11)

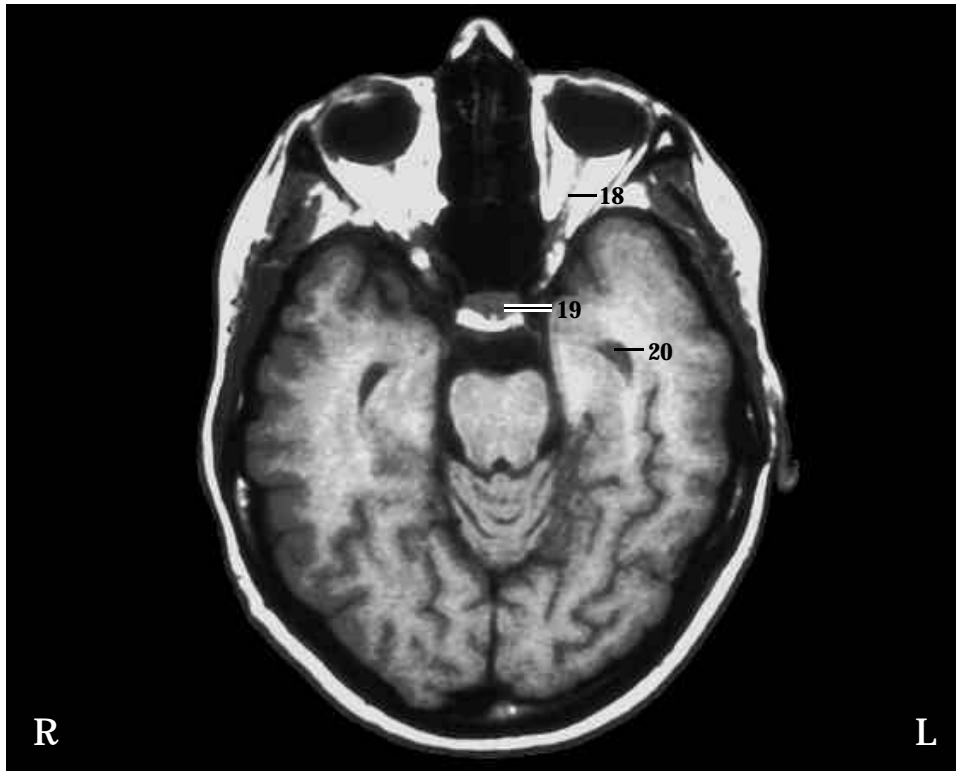
Nervous System

The cerebrum (6), midbrain, (7) and the cerebellum (9) are apparent (SST Figure 13-4). The cerebral aqueduct (8) extends inferiorly from the third ventricle (SST Figure 13-29). Within the transverse fissure, an extension of the dura mater called the tentorium cerebelli (10) separates the cerebrum and cerebellum. The falx cerebri (12) separates the cerebral hemispheres.

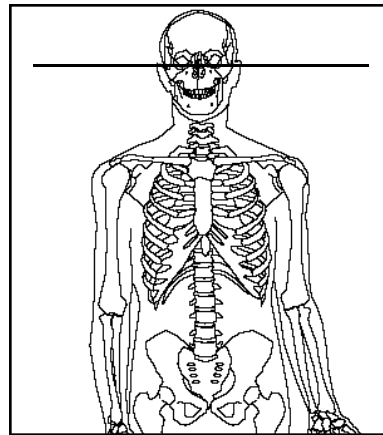
The sclera (16) and lens (17) of the eye are present on the right side (SST Figure 15-13), but only fat within the orbit is visible on the left side. It is not unusual for a section to reveal that the eyes are not exactly level with each other. In this case, the section is not perfectly horizontal, contributing to the impression that the eyes are not on the same level.

Skeletal System

Note the perpendicular plate of the ethmoid bone (1) and the air cells of the ethmoidal sinus (2) (SST Figure 7-2, F and 7-11). The sphenoidal sinus (3) within the sphenoid bone is posterior to the ethmoidal sinus (SST Figure 7-10 and 7-11).

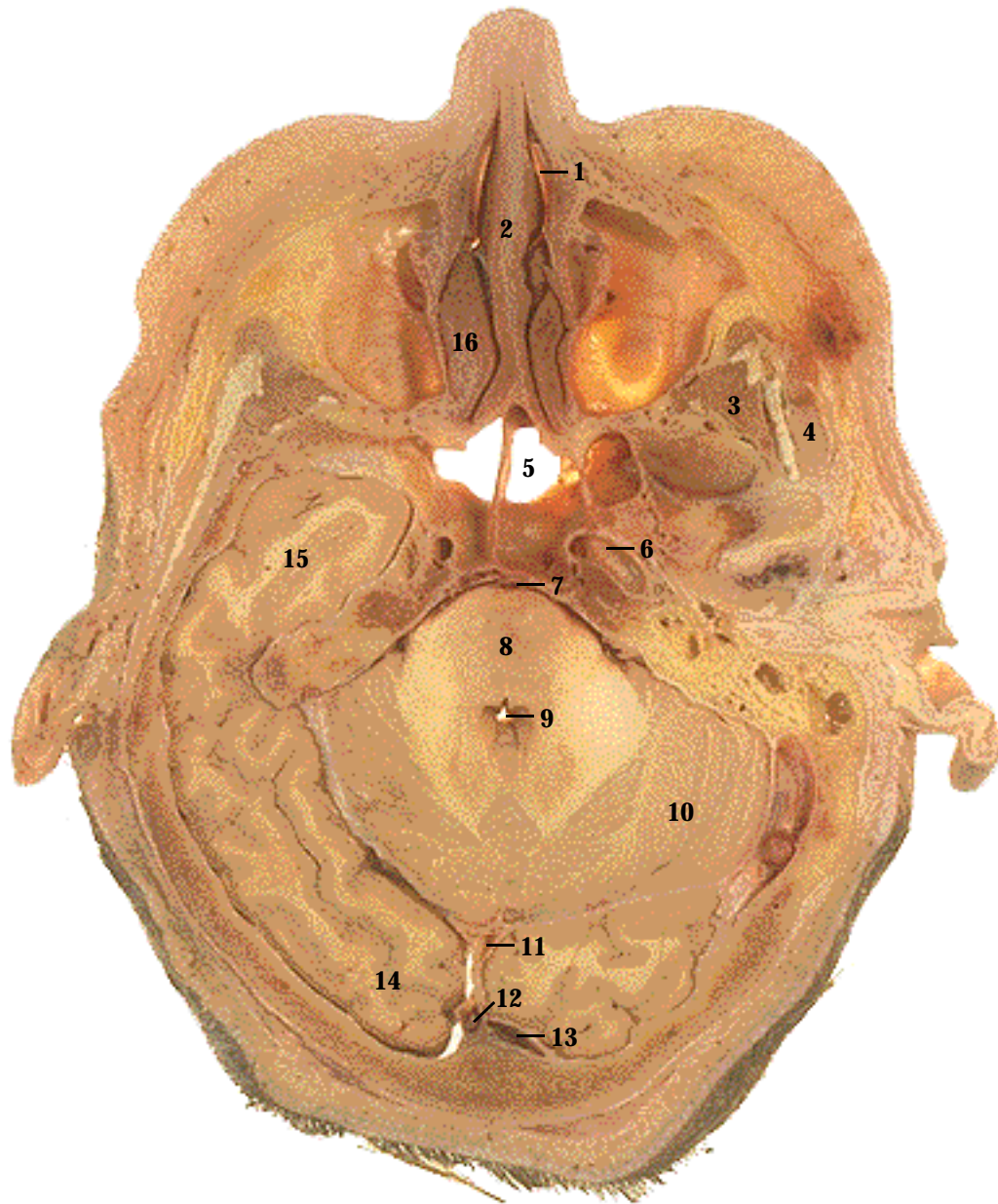


T1 MRI image. The air-filled ethmoidal sinus appear black. The MRI section is slightly superior to the cadaver section, demonstrating some additional structures. MRI is typically used for viewing the soft tissues of the skull because structures such as the optic nerves (18) show up on MRI but not CT. The white area posterior to the ethmoidal sinus is tissue, including the pituitary gland (19), located in the sella turcica of the sphenoid bone. The MRI also shows the anterior part of the lateral ventricles (20).



Level: Through the orbit, 12 mm below Section 2.

SECTION 3



1. Nasal cavity
2. Perpendicular plate of the ethmoid bone
3. Temporalis muscle
4. Masseter muscle
5. Sphenoidal sinus
6. Internal carotid artery
7. Basilar artery
8. Pons
9. Fourth ventricle
10. Cerebellum
11. Straight sinus
12. Superior sagittal sinus
13. Transverse sinus
14. Occipital lobe
15. Temporal lobe
16. Middle nasal concha

Systemic Descriptions

Cardiovascular System

The straight sinus (11) and transverse sinus (13) are cut close to their junction with the superior sagittal sinus (12) (SST Figure 21-13). The internal carotid artery (6) within the carotid canal is visible (SST Figure 7-13 and 21-7 A and B). The basilar artery (7) is on the anterior surface of the pons (SST Figure 21-7, B)

Muscular System

Two muscles of mastication can be seen in this section. The temporalis (3) is deep to the masseter (4) (SST Figure 11-6, A and 11-8, A).

Nervous System

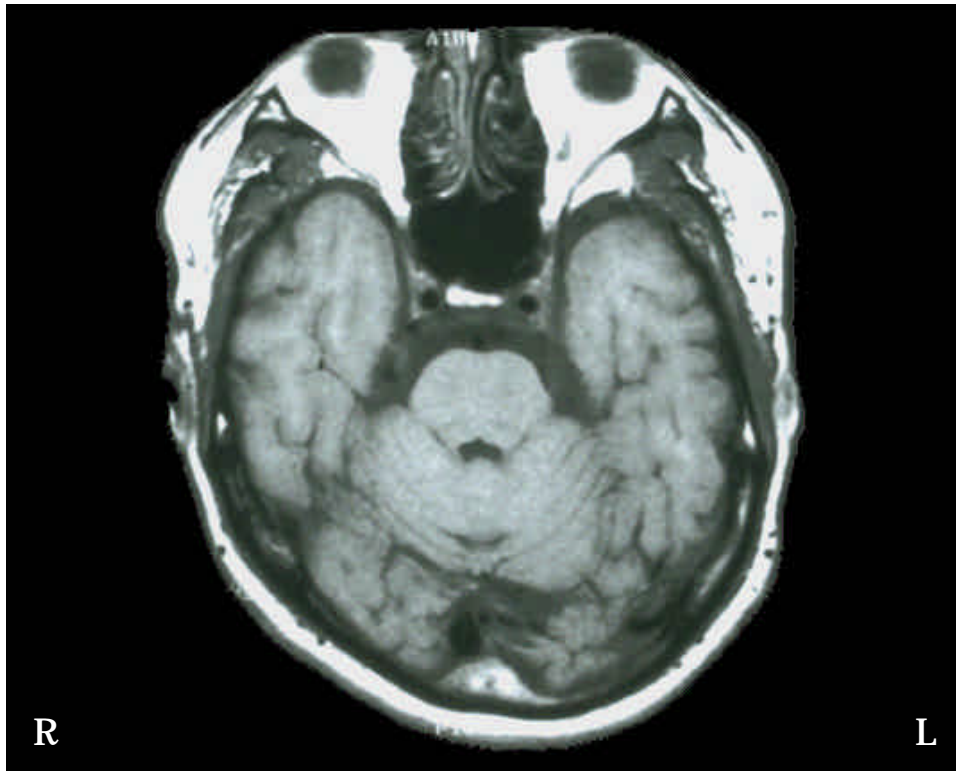
A small part of the temporal (15) and occipital (14) lobes of the cerebrum are still visible at this level, but the pons (8) and cerebellum (10) are the major brain features present (SST Figure 13-4). The cerebral aqueduct from Section 3 connects to the fourth ventricle (9) (SST Figure 13-29).

Respiratory System

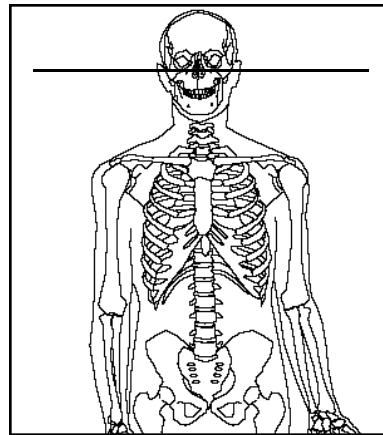
The nasal cavity (1) is visible (SST Figure 23-2).

Skeletal System

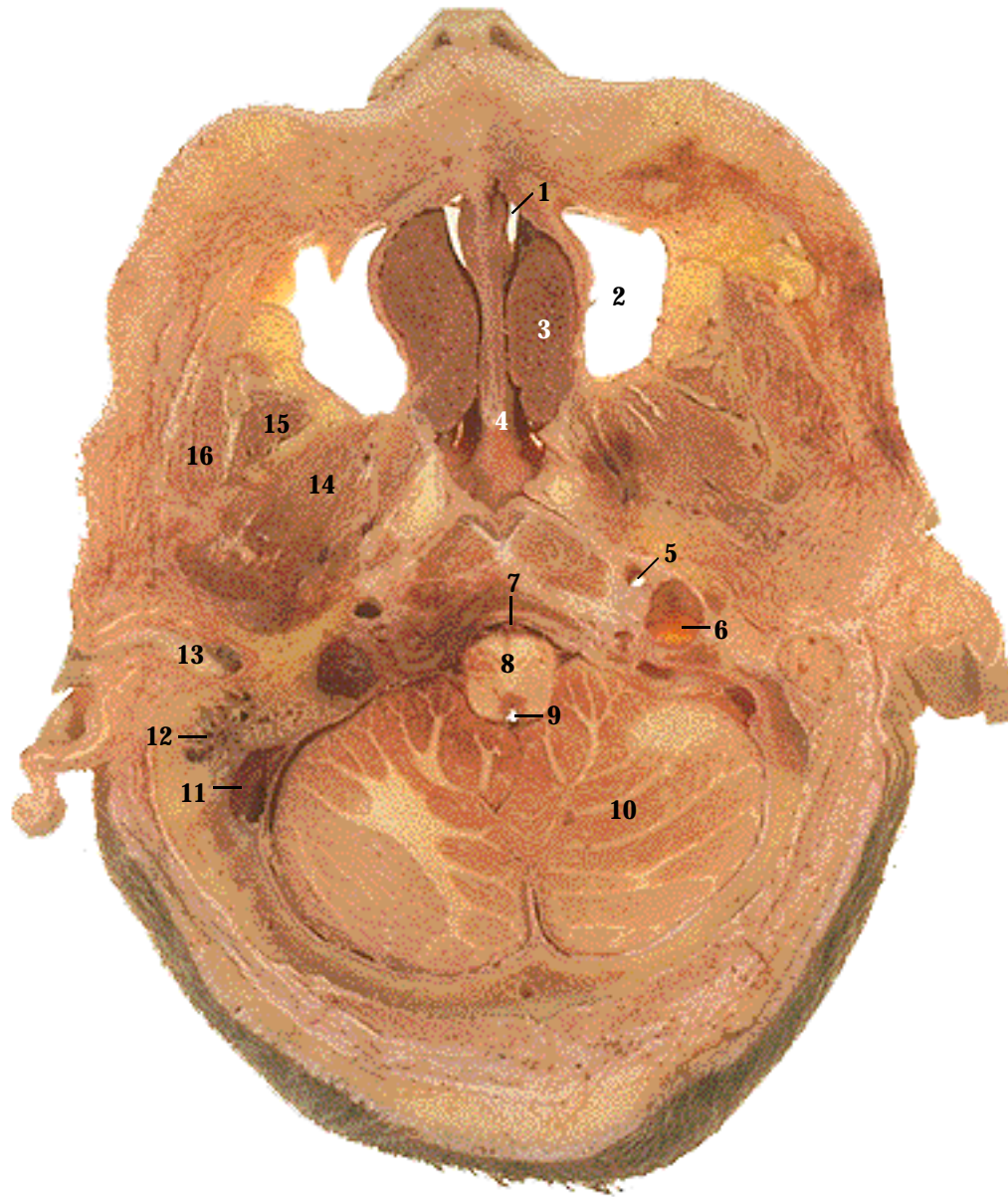
The middle nasal conchae (16) can be seen on either side of the perpendicular plate of the ethmoid bone (2). The sphenoidal sinus (5) is located posterior to the conchae (SST Figure 7-10).



T1 MRI image. Note the fourth ventricle posterior to the pons and the basilar artery anterior to the pons. The basilar artery and the two internal carotid arteries form the points of a triangle. Not seen on the cadaver section, the vitreous humor within the eyes appears as a dark gray in the MRI.



Level: Just inferior to the orbits.



1. Nasal cavity
2. Maxillary sinus
3. Inferior nasal concha
4. Vomer
5. Internal carotid artery
6. Internal jugular vein
7. Basilar artery
8. Medulla
9. Fourth Ventricle
10. Cerebellum
11. Sigmoid sinus
12. Mastoid air cells
13. External auditory meatus
14. Lateral pterygoid muscle
15. Temporalis muscle
16. Masseter muscle

Systemic Descriptions

Cardiovascular System

The internal carotid artery (5) (SST Figure 21-7, B) is located anterior to the internal jugular vein (6) (SST Figure 21-13). The basilar artery (7) is found just anterior to the medulla (SST Figures 21-7, B). The internal carotid arteries and basilar artery join the cerebral arterial circle (circle of Willis) superior to the level of this section (SST Figure 21-7, A). Note also the sigmoid sinus (11) as it passes anteriorly to join with the internal jugular vein (SST Figure 21-13).

Muscular System

Three muscles of mastication are visible (SST Figure 11-8). From superficial to deep, they are the masseter (16), temporalis (15), and the lateral pterygoid (14) muscles.

Nervous System

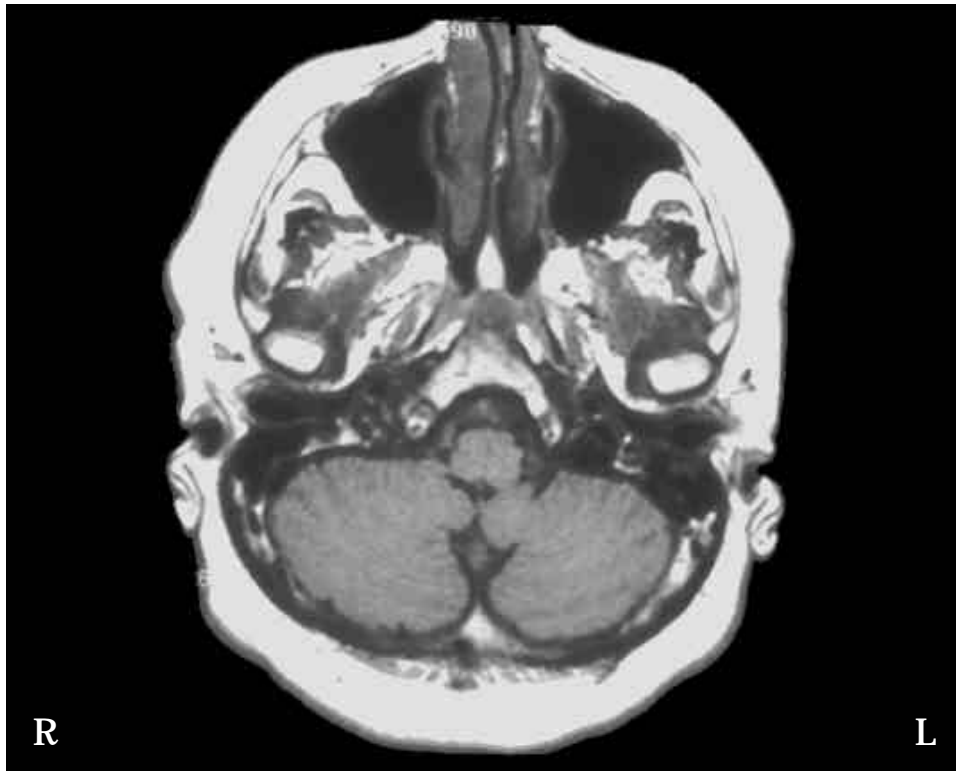
This section is below the level of the cerebrum. The medulla (8) and the lateral lobes of the cerebellum (10) can be seen (SST Figure 13-4). The fourth ventricle (9) is associated with the pons (see Section 4) and the superior half of the medulla. In the inferior half of the medulla, the fourth ventricle narrows to form the central canal, which continues inferiorly into the spinal cord (SST Figure 13-29).

Respiratory System

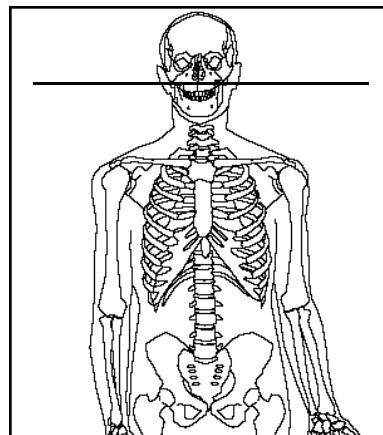
The nasal cavity (1) (SST Figure 23-2).

Skeletal System

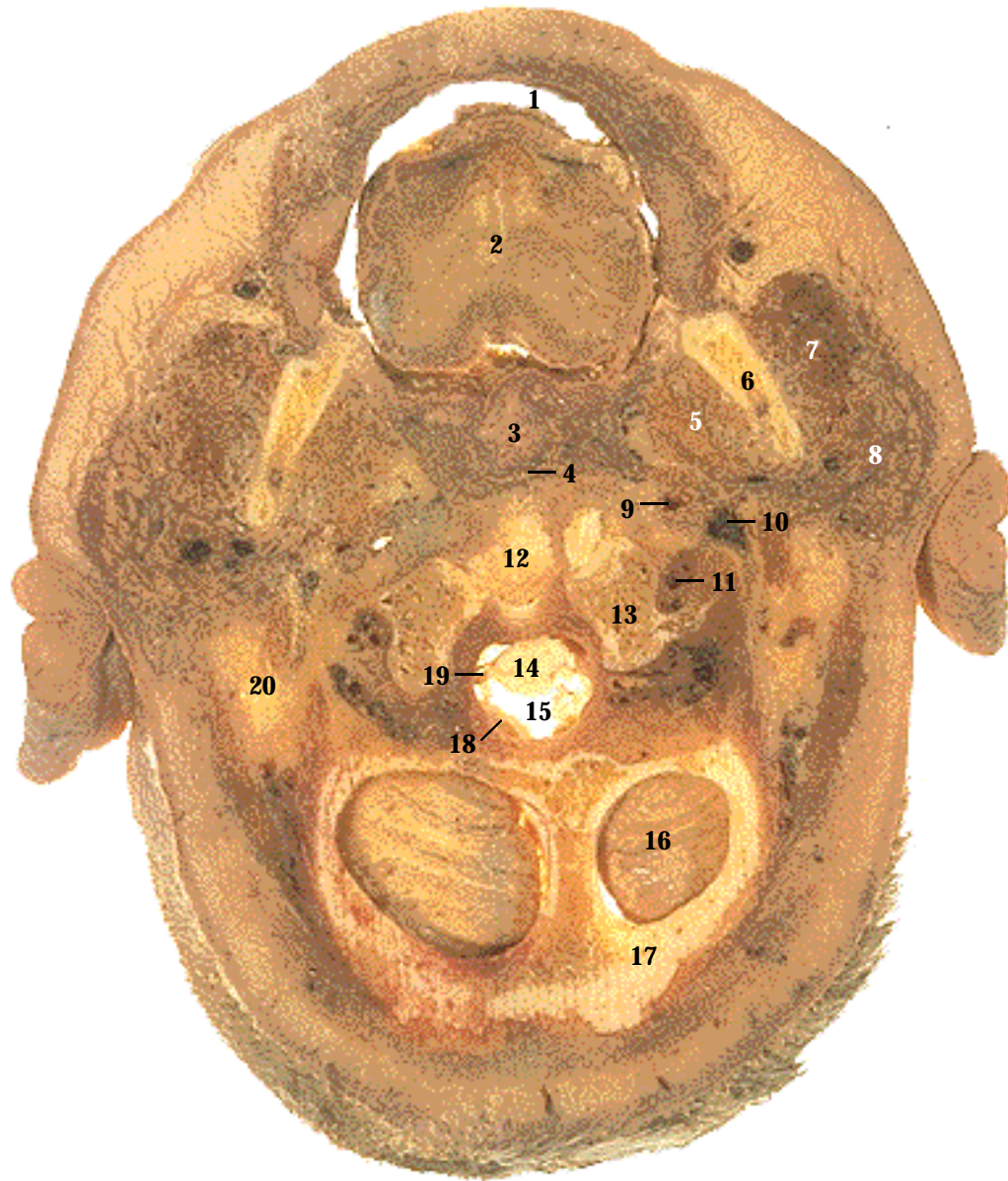
The vomer (4) forms the inferior part of the nasal septum, which divides the nasal cavity (1). The inferior nasal conchae (3) are located lateral to the vomer (SST Figure 7-10). The maxillary sinuses (2) are the largest paranasal sinuses (SST Figure 7-11). The external auditory meatus (13) extends into the temporal bone (SST Figure 15-23), and the mastoid air cells (12) are visible within the mastoid process of the temporal bone (SST Figure 7-5).



T1 MRI image. The air-filled maxillary sinuses appear black, as does the air within the nasal cavity on either side of the nasal septum. The muscles of mastication appear gray, and they are surrounded by fat and connective tissue, which appears white. The external auditory meatus, mastoid air cells, and sigmoid sinus appear black.



Level: Through the nasal cavity, 12 mm below the orbits.



1. Oral cavity
2. Tongue
3. Uvula
4. Collapsed connection between the nasopharynx and oropharynx
5. Medial pterygoid muscle
6. Ramus of mandible
7. Masseter muscle
8. Parotid salivary gland
9. Internal carotid artery
10. Internal jugular vein
11. Vertebral artery
12. Dens of axis (second cervical vertebra)
13. Atlas (first cervical vertebra)
14. Spinal cord
15. Subarachnoid space
16. Cerebellum
17. Occipital bone
18. Meninges
19. Denticulate ligament
20. Mastoid process of temporal bone
21. Oropharynx (MRI only)

Systemic Descriptions

Cardiovascular System

The internal carotid arteries (9) and the vertebral arteries (11) supply the brain with blood (SST Figure 21-7, A and B). Blood from the brain enters venous sinuses (see more superior sections) and exits the skull through the internal jugular veins (10) (SST Figure 21-13). The internal jugular vein is larger than the internal carotid artery.

Digestive System

The oral cavity (1) contains the tongue (2), and the parotid glands (8) are lateral to the mandibular rami (SST Figure 24-7, A).

Muscular System

The masseter (7) continues inferiorly from Section 5. The medial pterygoid (5) attaches to the medial surface of the mandible (SST Figure 11-8, B). The tongue (2) is within the oral cavity (SST Figure 11-10).

Nervous System

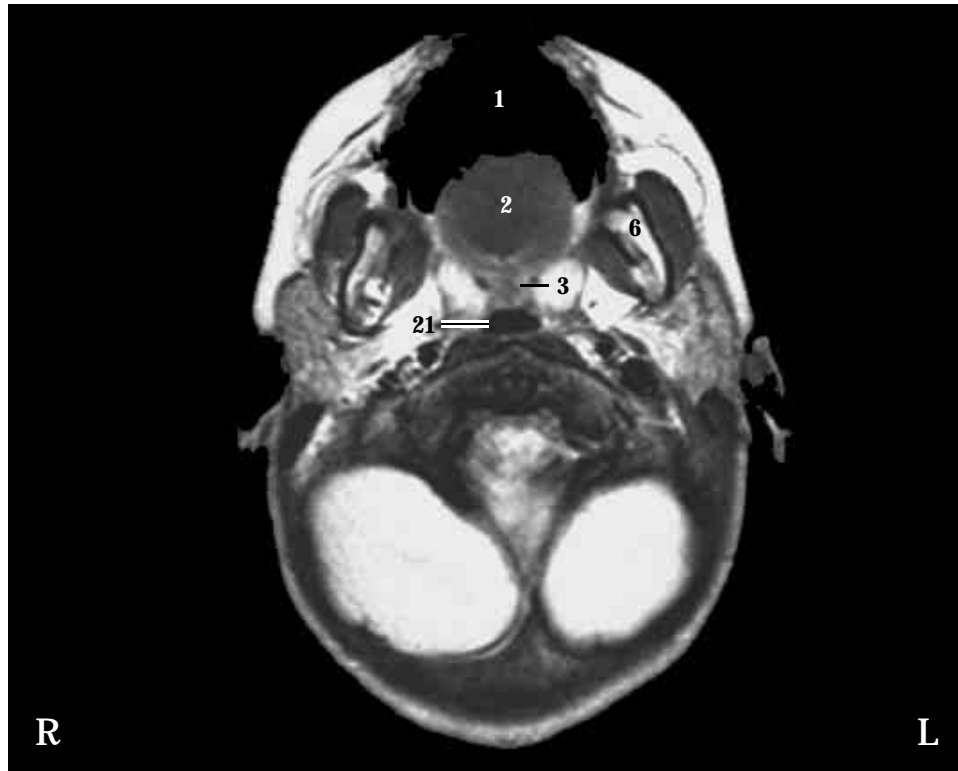
The spinal cord (14) and cerebellum (16) (SST Figure 13-8, B). The spinal cord is surrounded by the meninges (18) and the subarachnoid space (15). Denticulate ligaments (19) hold the spinal cord in place (SST Figure 13-28, B).

Respiratory System

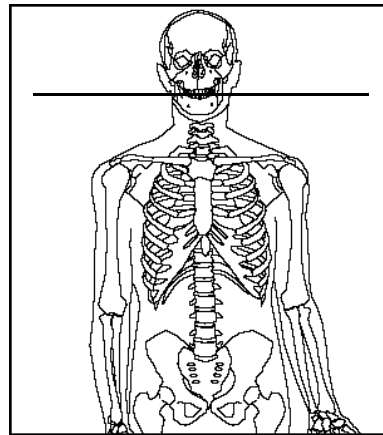
The uvula (3) of the soft palate has collapsed the connection (4) between the nasopharynx and the oropharynx (SST Figure 23-2, A). In life, closing this connection prevents swallowed materials from entering the nasopharynx.

Skeletal System

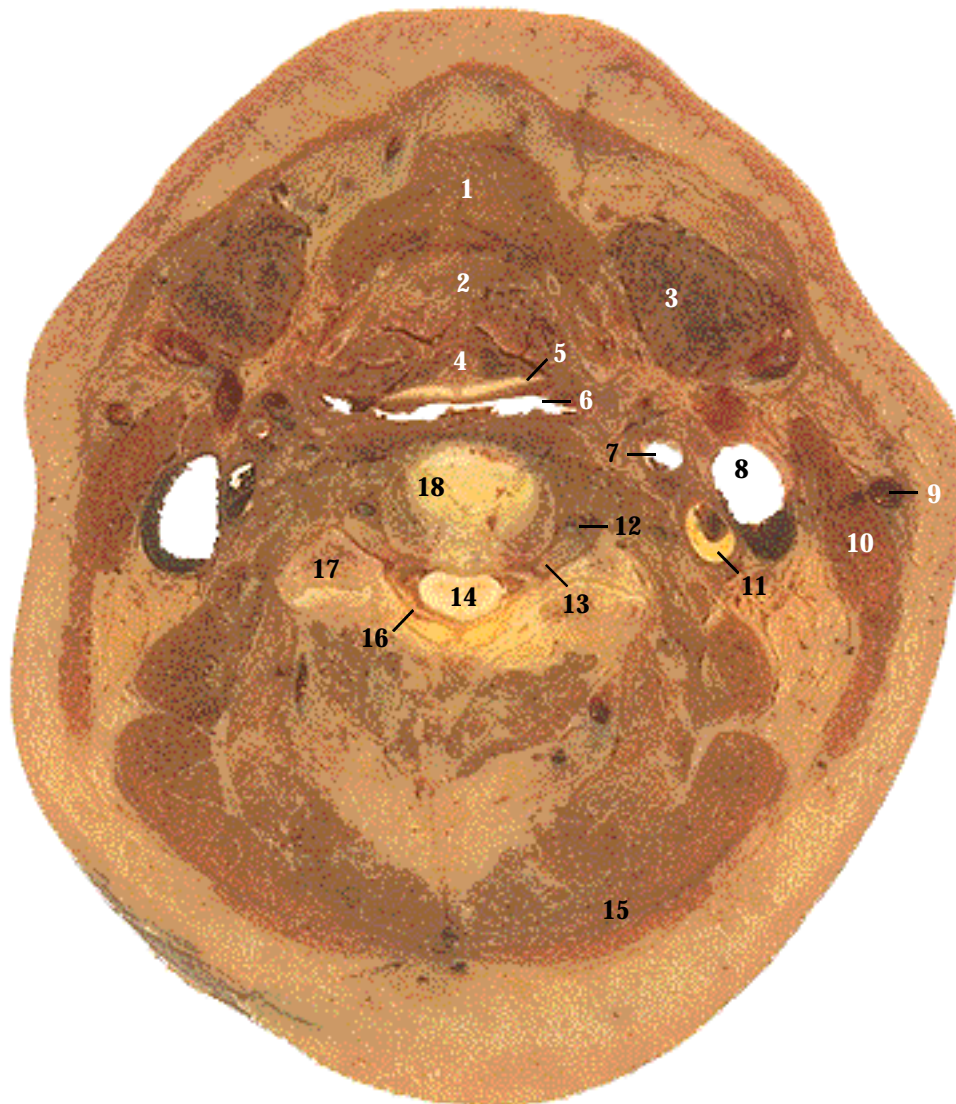
The ramus of the mandible (6), the mastoid process (20) of the temporal bone, and the inferior part of the occipital bone (17) are cut (SST Figure 7-5). The atlas (13) and dens (12) of the axis are also sectioned (SST Figure 7-18, A and B).



T1 MRI image. The oral cavity (1) contains the tongue (2). Posteriorly, the uvula (3) of the soft palate extends into the oropharynx (21). In the cadaver section, the connection (4) between the nasopharynx and oropharynx is collapsed. Use the ramus of the mandible (6) as a landmark. The masseter is lateral to the ramus, and the medial pterygoid is medial to the ramus.



Level: Through the oral cavity.



1. Suprahyoid muscle (geniohyoid)
2. Extrinsic tongue muscle (genioglossus)
3. Submandibular salivary gland
4. Tongue
5. Epiglottis
6. Laryngopharynx
7. External carotid artery
8. Internal jugular vein
9. External jugular vein
10. Sternocleidomastoid muscle
11. Internal carotid artery
12. Vertebral artery
13. Spinal nerve
14. Spinal cord
15. Trapezius muscle
16. Dura mater
17. Transverse process of vertebra
18. Body of cervical vertebra
19. Mandible (CT only)
20. Vallecule (CT only)

Systemic Descriptions

Cardiovascular System

The external carotid arteries (7) supply the neck, throat, and mouth (SST Figure 21-7, A). The external jugular veins (9) drain the superficial surface of the head and neck (SST Figure 21-14). At this level, the external carotid artery is anterior and medial to the internal carotid artery (11). Note the arteriosclerotic plaque within the left internal carotid artery. The sternocleidomastoid muscle separates the internal jugular vein (8) from the more superficial external jugular vein. The vertebral arteries (12) are within the transverse foramina of the cervical vertebra (SST Figure 21-7, A).

Digestive System

Part of the submandibular salivary glands (3) are located inferior to the mandible (SST Figure 24-7, A). The laryngopharynx (6) connects inferiorly to the esophagus (SST Figure 23-2, A).

Muscular System

A suprahyoid muscle (geniohyoid) (1) is cut between its attachment to the hyoid bone and mandible (SST Figure 11-10). An extrinsic tongue muscle (genioglossus) (2) attaches to the base of the tongue (4) (SST Figure 23-2, A). The sternocleidomastoid muscle (10), the trapezius (15), and other neck muscles are also evident (SST Figure 11-4).

Nervous System

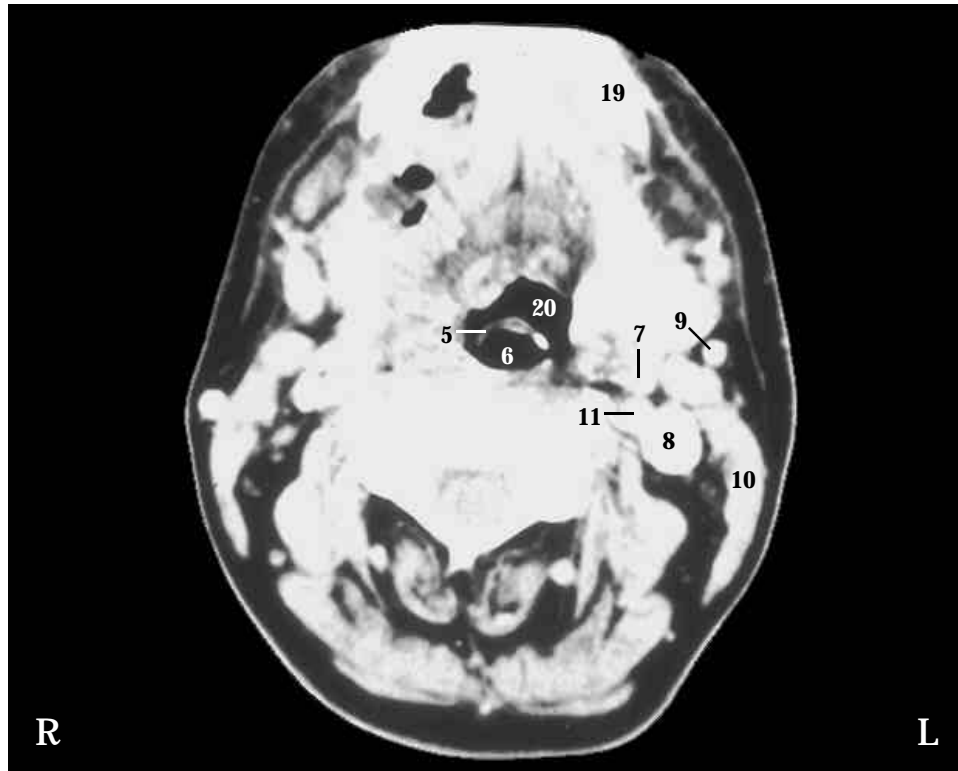
A spinal nerve (13) exits the spinal cord (14) (SST Figure 14-2). The dura mater (16) surrounds the spinal cord (SST Figure 13-28).

Respiratory System

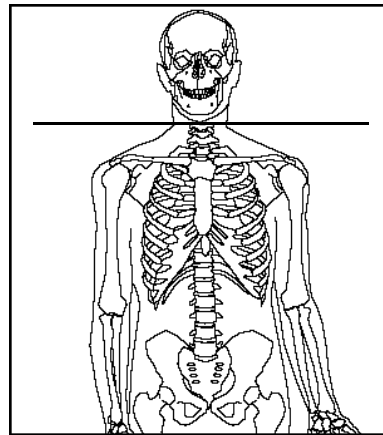
The epiglottis (5) forms the superior part of the larynx (SST Figure 23-2, A and 23-3).

Skeletal System

The body (18) and transverse processes (17) of a cervical vertebra (SST Figure 7-18, C).

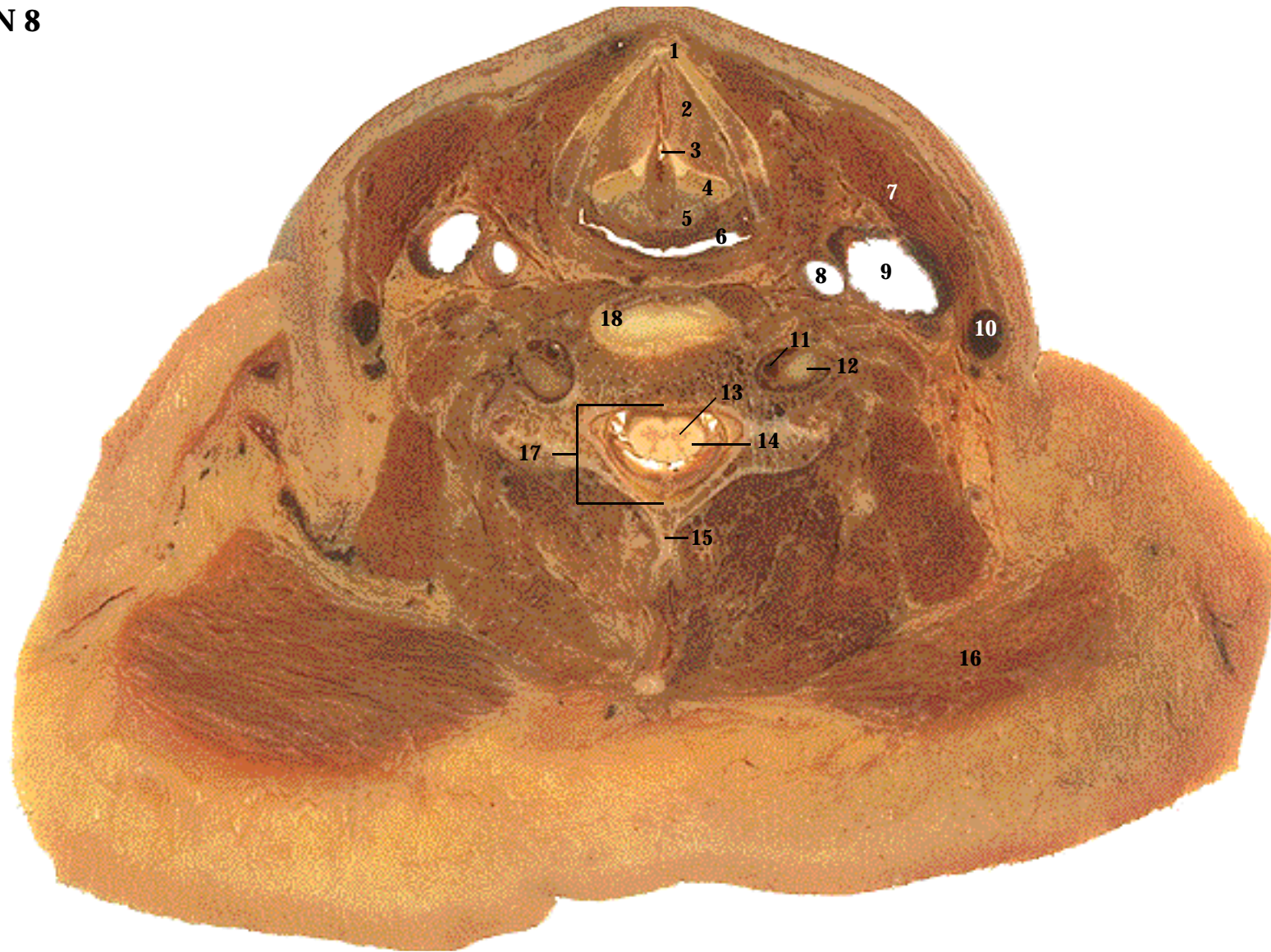


CT image. In CT images, fat appears dark gray to black, whereas bone and cartilage appear white. Air-filled spaces, such as within the laryngopharynx, appear black. Contrast media within the blood vessels appears white. An outer white or gray border is sometimes seen around a CT section. It is an artifact produced at air-tissue interfaces. A portion of the mandible (19) and the vallecule (20) are visible in the CT, but not in the cadaver section. The vallecule is a depression between the epiglottis and the tongue.



Level: Through C4. The neck, inferior to the mandible.

SECTION 7



1. Thyroid cartilage of larynx
2. Vocal cords
3. Laryngeal cavity
4. Arytenoid cartilage of larynx
5. Cricoid cartilage of larynx
6. Laryngopharynx

7. Sternocleidomastoid muscle
8. Common carotid artery
9. Internal jugular vein
10. External jugular vein
11. Vertebral artery
12. Spinal nerve

13. Gray matter of spinal cord
14. White matter of spinal cord
15. Spinous process of vertebra
16. Trapezius muscle
17. Vertebral foramen
18. Body of cervical vertebra

Systemic Descriptions

Cardiovascular System

Internal (9) and external jugular (10) veins are present (SST Figure 21-14). The common carotid artery (8) is cut inferior to the bifurcation of the common carotid into the internal carotid and external carotid arteries (see Section 7). The vertebral arteries (11) are present (SST Figure 21-7, A). The internal jugular vein lies between the external jugular vein and the common carotid artery.

Digestive System

The laryngopharynx (6) is evident immediately posterior to the larynx (SST Figure 23-2).

Muscular System

The sternocleidomastoid muscle (7), the trapezius (16), and other neck muscles are evident (SST Figure 11-4).

Nervous System

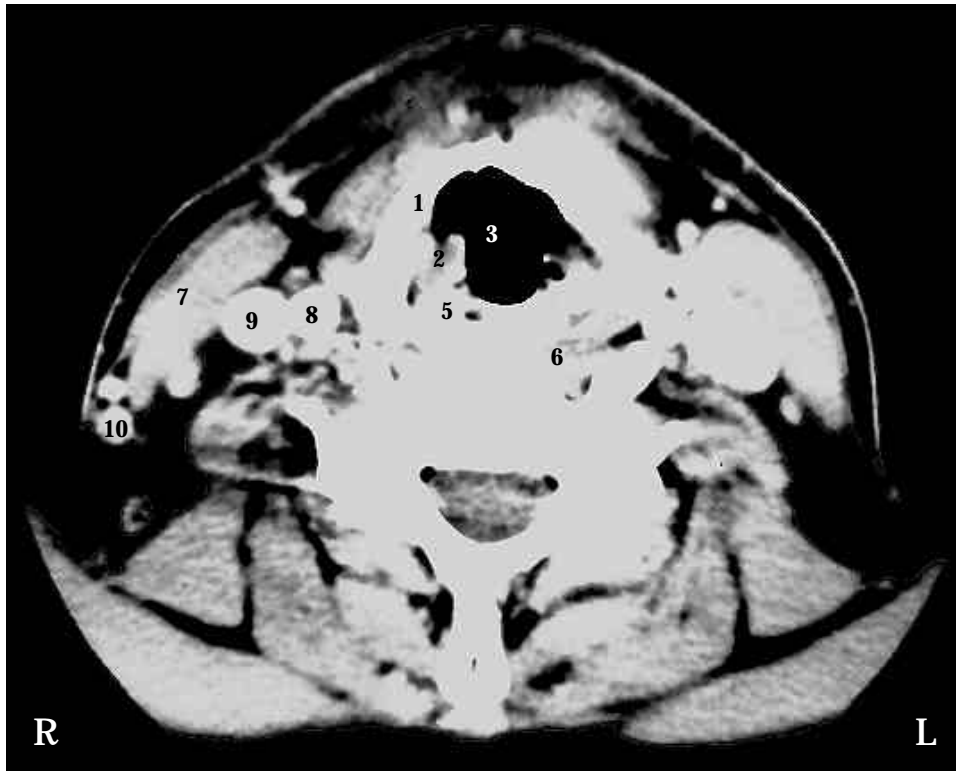
The spinal cord continues inferiorly. Note the internal gray matter (13) and the outer white matter nerve tracts (14) of the spinal cord (SST Figure 13-19). Spinal nerves (12) are cut next to the cervical vertebra.

Respiratory System

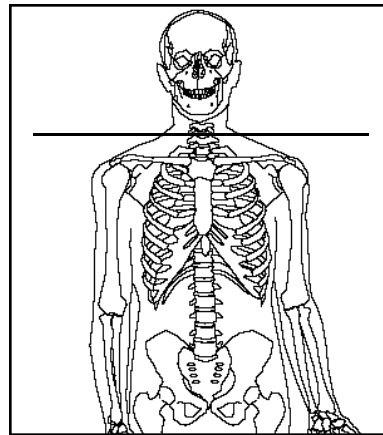
Several of the cartilages forming the larynx are present (SST Figure 23-2, A and 23-3). The inferior part of the thyroid cartilage (1) and part of the cricoid (5) and arytenoid cartilages (4) are visible. The vocal cords (2), or vocal folds, are separated by the laryngeal cavity (3) (SST Figure 23-4).

Skeletal System

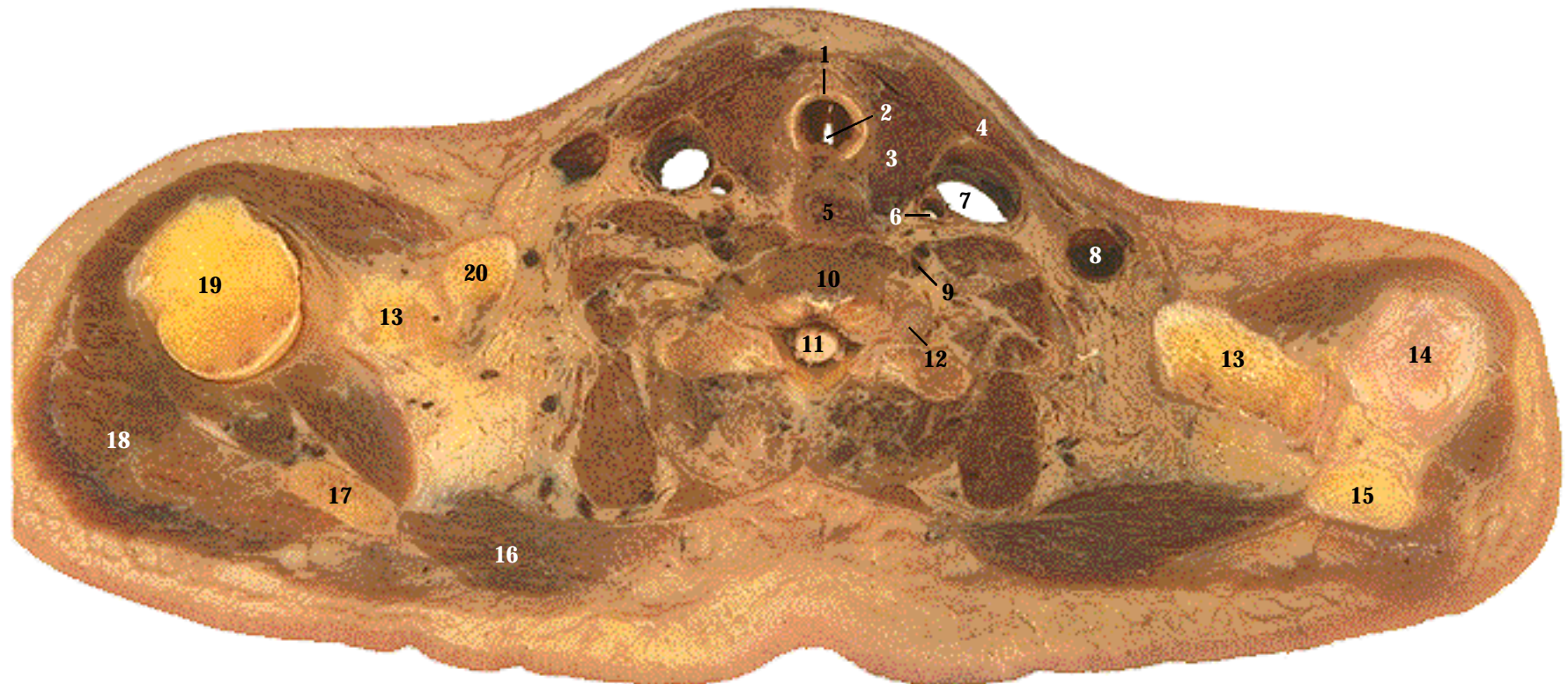
The vertebral foramen (17) is occupied by the spinal cord and meninges (SST Figure 7-15). Note the bifid spinous process (15) and the body (18) of the cervical vertebra (SST Figure 7-18, C).



CT images. A classic view of the larynx, showing the anterior v-shaped thyroid cartilage and the posterior cricoid cartilage. The air-filled laryngeal cavity is black, with small portions of the gray-colored vocal cords located laterally. The gray-colored spinal cord is within the vertebral foramen.



Level: Through C6. The neck, at its junction with the shoulders.



- | | | |
|---------------------------------|---------------------------------|---------------------------------|
| 1. Trachea (C-shaped cartilage) | 8. External jugular vein | 15. Acromion process of scapula |
| 2. Cavity of trachea | 9. Vertebral artery | 16. Trapezius muscle |
| 3. Thyroid gland | 10. Body of cervical vertebrae | 17. Spine of scapula |
| 4. Sternocleidomastoid muscle | 11. Spinal cord | 18. Deltoid muscle |
| 5. Esophagus | 12. Spinal nerve | 19. Head of humerus |
| 6. Common carotid artery | 13. Coracoid process of scapula | 20. Clavicle |
| 7. Internal jugular vein | 14. Joint capsule | |

Systemic Descriptions

Cardiovascular System

The common carotid arteries (6) and the vertebral arteries (9) extend superiorly (SST Figure 21-7, A), whereas the internal jugular (7) and external jugular (8) veins descend (SST Figure 21-14).

Digestive System

The esophagus (5) is located posterior to the trachea and anterior to the vertebral body (SST Figure 23-2). The esophagus continues inferiorly (SST Figure 24-1).

Endocrine System

The lobes of the thyroid gland (3) are located beside the trachea (SST Figure 18-7, A).

Muscular System

The sternocleidomastoid (4), trapezius (16), deltoid (18) and other muscles are visible in this section (SST Figures 11-3 and 11-4).

Nervous System

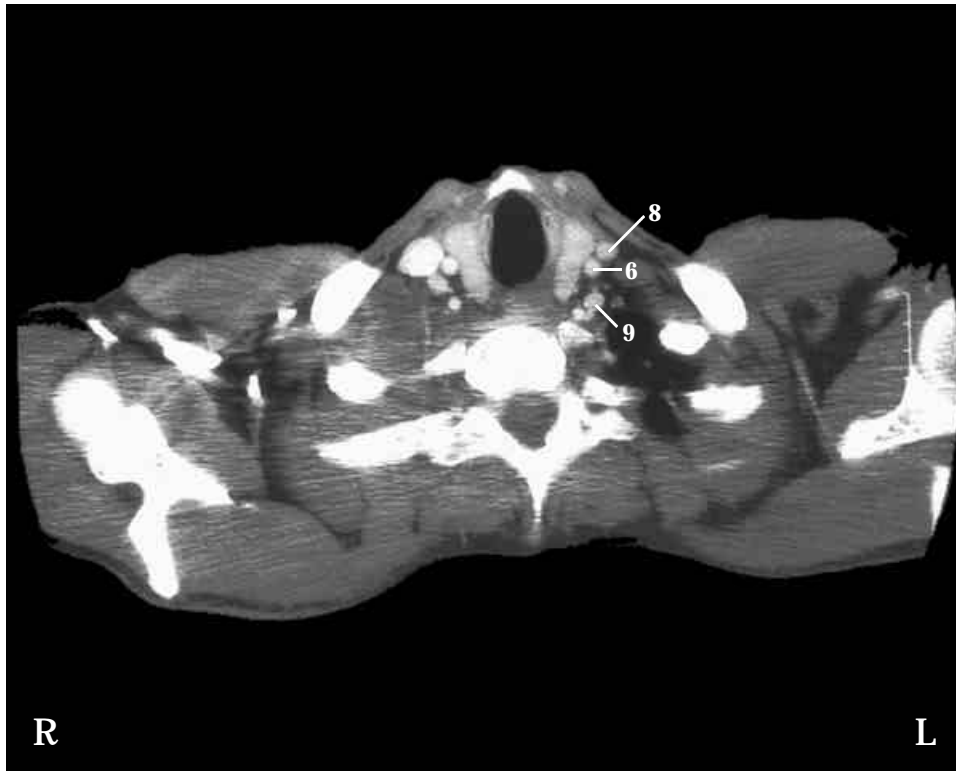
The spinal cord (11) continues inferiorly. Spinal nerves (12) extend away from the vertebra.

Respiratory System

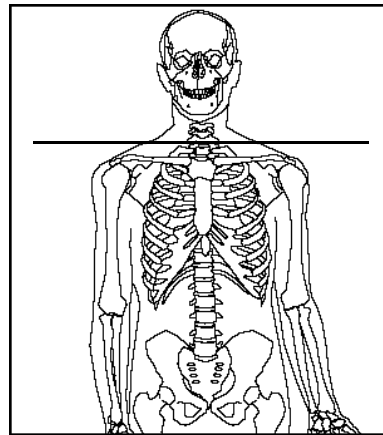
The trachea is anterior to the esophagus. Note the C-shaped cartilage (1) of the tracheal wall and the cavity of the trachea (2) (SST Figure 23-3 and 23-5, A).

Skeletal System

The vertebral body (10) is posterior to the esophagus. On the right side, the head of the humerus (19), the spine (17) and the coracoid process (13) of the scapula, and the clavicle (20) are cut. On the left side, the acromion process (15), coracoid process (13), and superior part of the shoulder joint capsule (14) are cut (SST Figure 7-1 and 7-21).

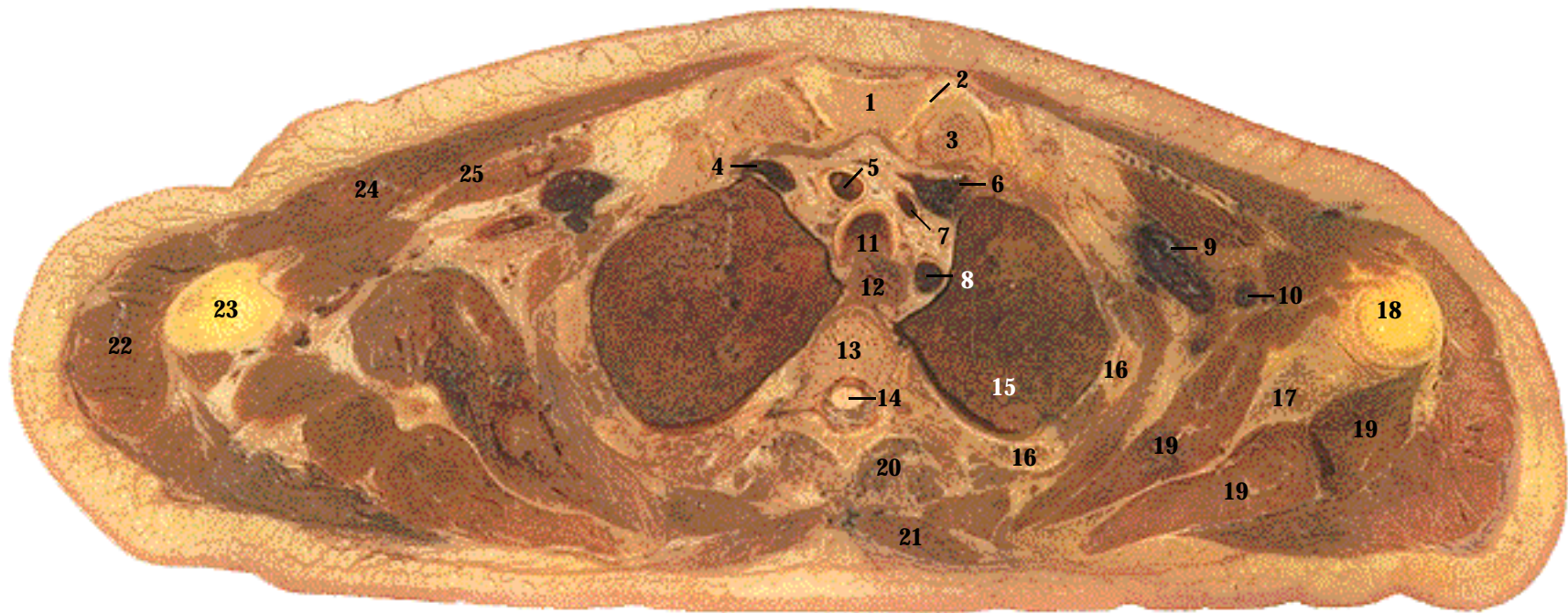


CT image. The gray-colored thyroid gland is located lateral to the air-filled trachea, which appears black. The gray-colored tissue posterior to the trachea is the esophagus. Immediately posterior to the esophagus is the body of the vertebrae. In addition to the vertebra, other white-colored bones are apparent. Also note the many gray-colored muscles. The streaked appearance is an artifact produced because the computer has difficulty distinguishing between bone and surrounding soft tissue.



Level: Through C7. The neck and superior aspect of the shoulders.

SECTION 9



- | | | |
|-------------------------------|----------------------|-----------------------------|
| 1. Manubrium of sternum | 10. Axillary artery | 19. Rotator cuff muscles |
| 2. Articular disk | 11. Trachea | 20. Erector spinae muscles |
| 3. Clavicle | 12. Esophagus | 21. Trapezius muscle |
| 4. Right brachiocephalic vein | 13. Body of vertebra | 22. Deltoid muscle |
| 5. Brachiocephalic artery | 14. Spinal cord | 23. Shaft of humerus |
| 6. Left brachiocephalic vein | 15. Left lung | 24. Pectoralis major muscle |
| 7. Left common carotid artery | 16. Rib | 25. Pectoralis minor muscle |
| 8. Left subclavian artery | 17. Scapula | |
| 9. Axillary vein | 18. Head of humerus | |

Systemic Descriptions

Cardiovascular System

The brachiocephalic artery (5), left common carotid artery (7), and left subclavian artery (8) have just branched off the aortic arch (SST Figure 21-9, A). The right (4) and left (6) brachiocephalic veins are descending to join the superior vena cava (SST Figure 21-16). The axillary artery (10) and vein (9) are present (SST Figures 21-8 and 21-15).

Digestive System

The esophagus (12) continues inferiorly (SST Figure 24-1).

Muscular System

The pectoralis major (24) (SST Figure 11-20, A) and pectoralis minor (25) (SST Figure 11-19, B) are part of the anterior chest. The deltoid (22) and trapezius (21) muscles continue inferiorly (SST Figure 11-3). Note the rotator cuff muscles (19) on both sides of the scapula (SST Figure 11-20, B and 11-21). Erector spinae muscles (20) are along the midline of the back (SST Figure 11-13).

Nervous System

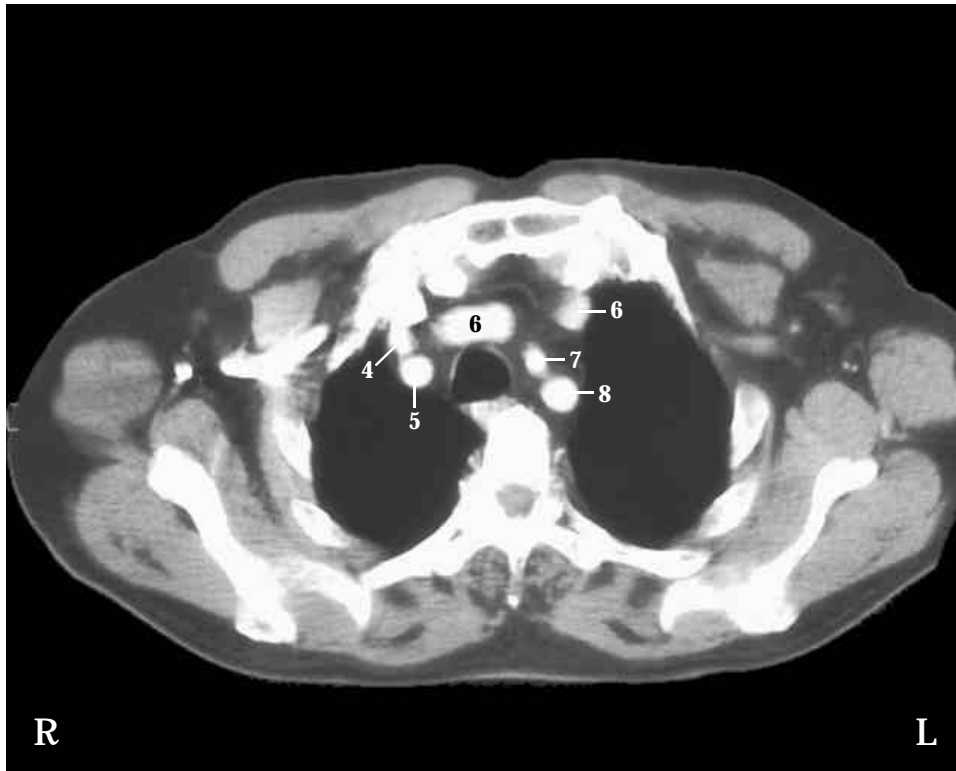
The spinal cord (14) continues inferiorly.

Respiratory System

The trachea (11) continues inferiorly from Section 9. The apical lobe (15) of each lung is present (SST Figure 23-6).

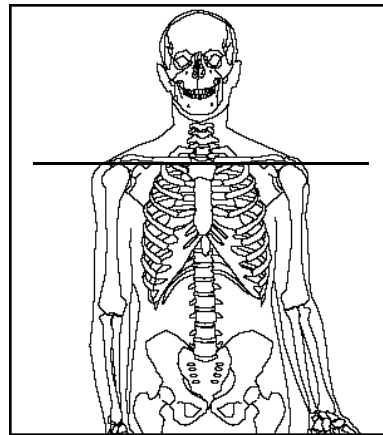
Skeletal System

Parts of the thoracic cage (SST Figure 7-19, A) are present: the manubrium of the sternum (1), ribs (16), and a thoracic vertebra (13). Because the ribs slant anteriorly, more than one rib can be cut at the same time. The manubrium is separated from each clavicle (3) by an articular disk (2) (SST Table 8-1). On the left side, the scapula (17) articulates with the head of the humerus (18). On the right side, the shaft of the humerus (23) has been cut (SST Figure 8-9, B).

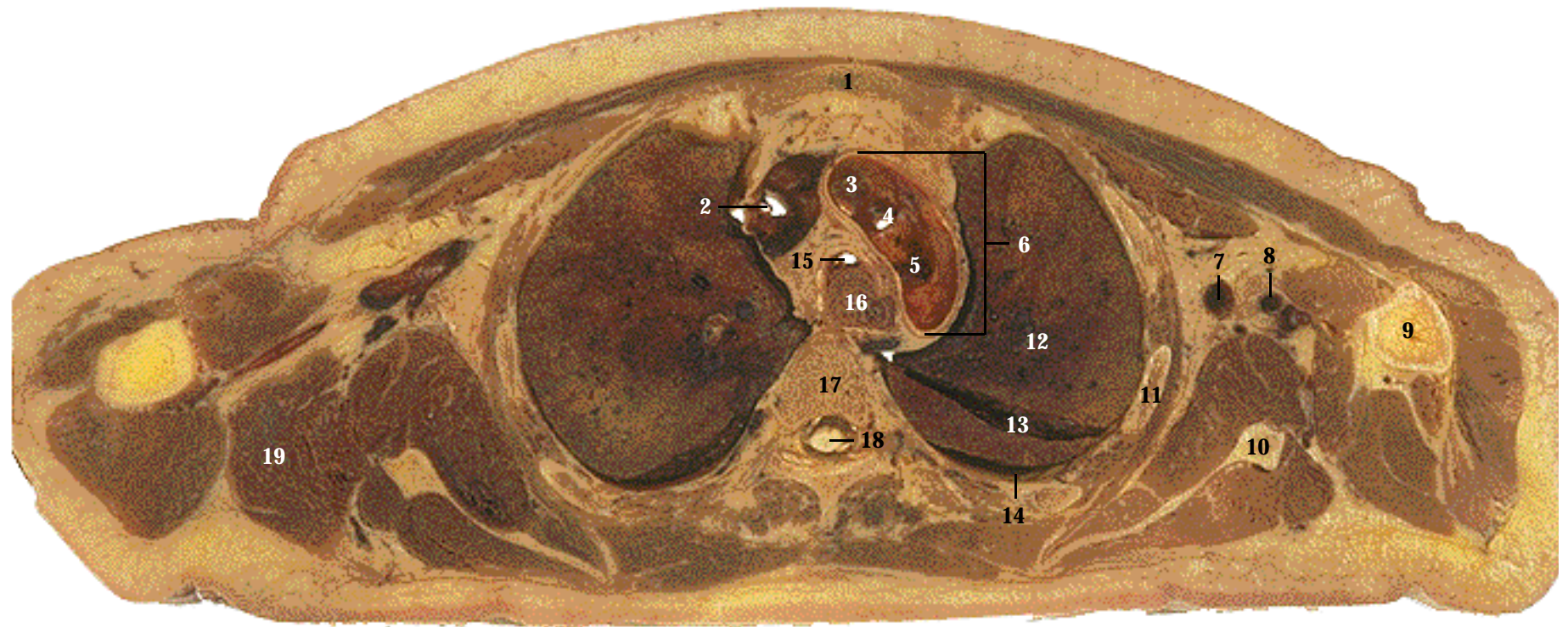


CT image. From anterior to posterior, note the relationship between the trachea, esophagus, and body of the vertebrae. Located around the trachea in a clockwise direction are the brachiocephalic, left common carotid, and left subclavian arteries. The left brachiocephalic vein has been cut in two places as it crosses over to the right side of the body to join the superior vena cava. One section through the left brachiocephalic vein appears elongated because it has been cut more longitudinally.

SECTION 10



Level: Through T3. Superior part of the thoracic cavity.



1. Manubrium of sternum
2. Superior vena cava
3. Brachiocephalic artery
4. Left common carotid artery
5. Left subclavian artery
6. Aortic arch
7. Axillary vein

8. Axillary artery
9. Humerus
10. Scapula
11. Rib
12. Left lung
13. Oblique fissure
14. Pleural cavity

15. Trachea
16. Esophagus
17. Body of vertebra
18. Spinal cord
19. Teres major muscle

Systemic Descriptions

Cardiovascular System

The aortic arch (6) is cut, revealing the openings to the brachiocephalic (3), left common carotid (4), and left subclavian (5) arteries, which project superiorly (SST Figure 21-9, A). The brachiocephalic veins from the previous section have joined to form the superior vena cava (2) (SST Figure 21-16). The axillary artery (8) and vein (7) are more laterally located at this level than in the previous section (SST Figures 21-8 and 21-15).

Digestive System

The esophagus (16) continues inferiorly.

Muscular System

The teres major (19) muscle is present (SST Figure 11-20, B). See Section 10 for other muscles.

Nervous System

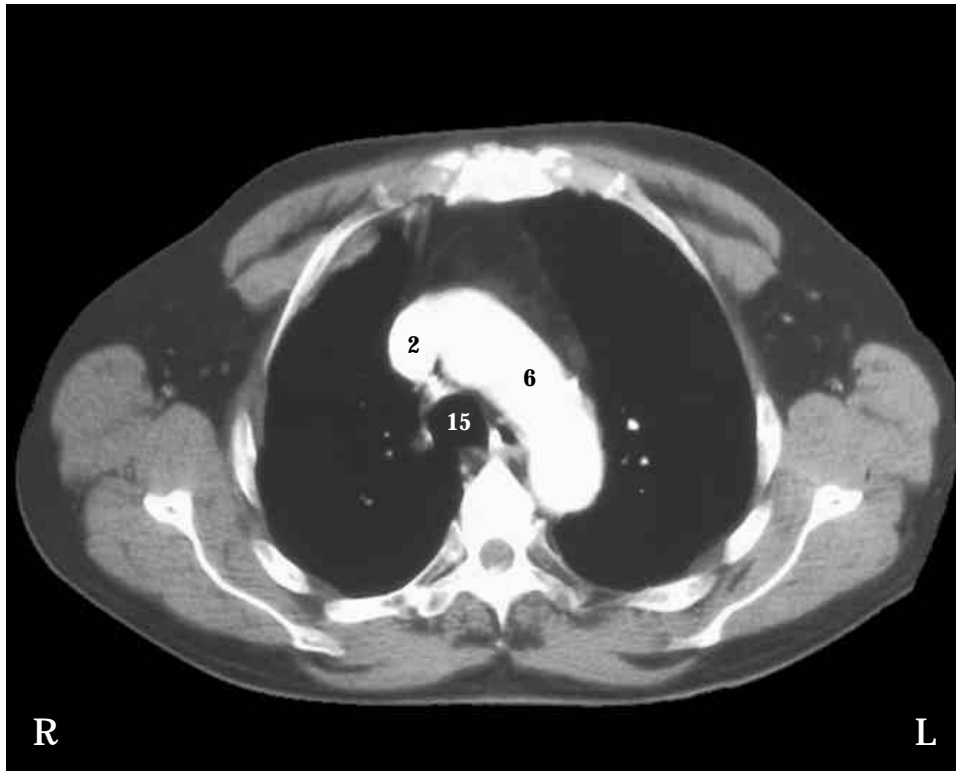
The spinal cord (18) continues inferiorly.

Respiratory System

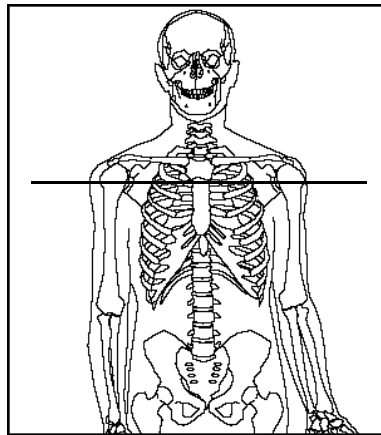
The trachea (15) continues inferiorly. Because the lungs are cone shaped, the cut through this part of the lungs is larger than in the previous section. Each lung is surrounded by a pleural cavity (14) within the thoracic cavity (SST Figure 23-7). Note the oblique fissure (13), which divides the left lung (12) into lobes (SST Figure 23-5).

Skeletal System

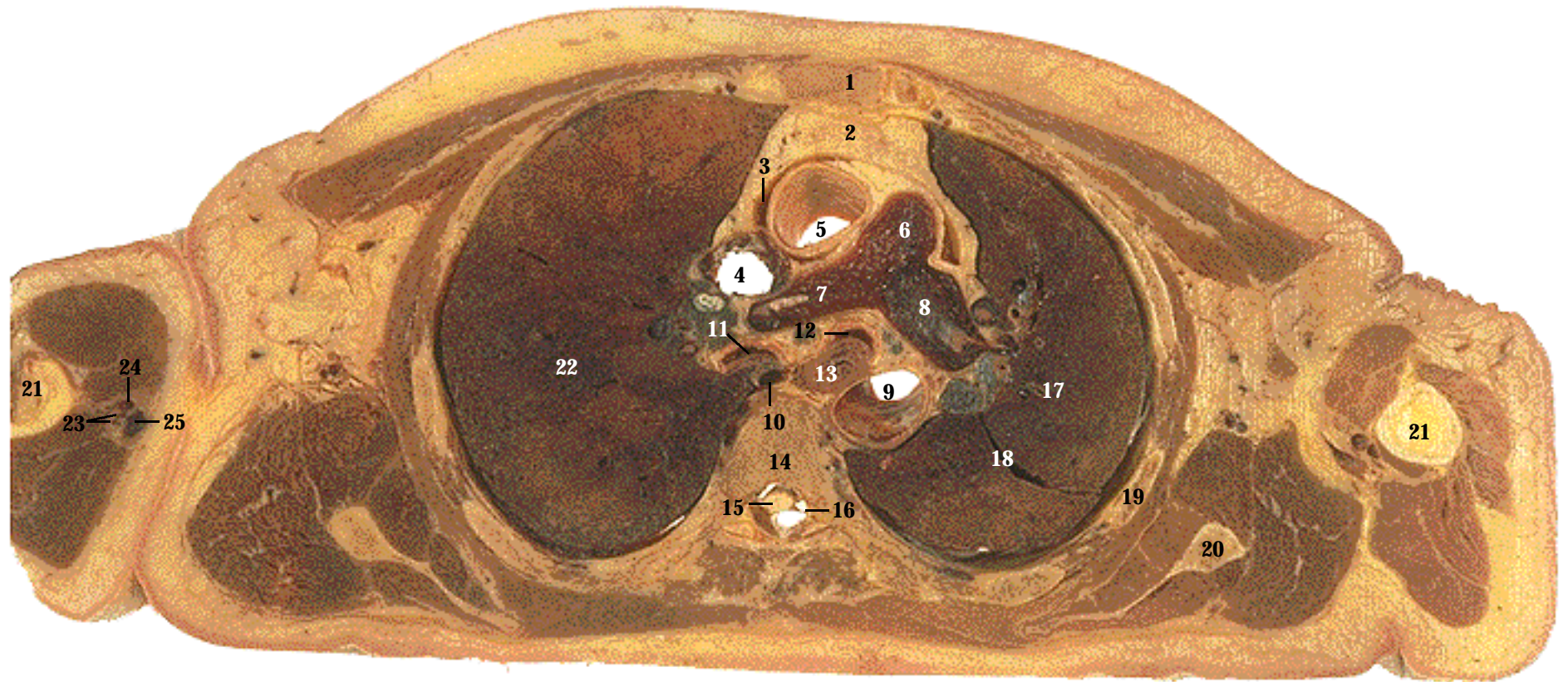
The manubrium of the sternum (1), the ribs (11), and a thoracic vertebra (17) form the boundary of the thoracic cavity. Both scapulae (10) and both humerus bones (9) are also present (SST Figure 7-19, A).



CT image. Note the relationship between the trachea, esophagus, and body of vertebrae. The aortic arch has been cut longitudinally and appears white because it contains contrast media. The superior vena cava is located to the right of the aortic arch. The air-filled lungs appear black. The white dots within the lungs are pulmonary vessels containing contrast media. Note the ribs attaching to the transverse processes and body of the vertebra.



Level: Through T4. Thorax, through the lungs and aortic arch.



- | | | |
|----------------------------------|----------------------------|---|
| 1. Body of sternum | 10. Azygos vein | 19. Rib |
| 2. Adipose tissue of mediastinum | 11. Right primary bronchus | 20. Scapula |
| 3. Pericardial cavity | 12. Left primary bronchus | 21. Humerus |
| 4. Superior vena cava | 13. Esophagus | 22. Right lung |
| 5. Ascending aorta | 14. Body of vertebra | 23. Brachial veins |
| 6. Pulmonary trunk | 15. Spinal cord | 24. Brachial artery |
| 7. Right pulmonary artery | 16. Spinal nerve | 25. Basilic vein |
| 8. Left pulmonary artery | 17. Left lung | 26. Trachea dividing to form right and left primary bronchi (CT only) |
| 9. Descending (thoracic) aorta | 18. Oblique fissure | |

Systemic Descriptions

Cardiovascular System

The ascending aorta (5) and descending (thoracic) aorta (9) are cut inferior to the aortic arch. The ascending aorta projects to the right upon leaving the left ventricle. The superior vena cava (4) lies next to the ascending aorta. Note the bifurcation of the pulmonary trunk (6) into the right (7) and left (8) pulmonary arteries. The pulmonary trunk projects to the left upon leaving the right ventricle. See SST Figure 20-6 for the relative location of these vessels. The superior part of the pericardial cavity (3) is visible (SST Figure 20-4). The brachial arteries (24) supply blood to the upper limbs and the basilic (25) and brachial veins (23) return blood (SST Figures 21-8 and 21-15). At this level, the basilic and brachial veins often anastomose and are difficult to distinguish. The azygos vein (10), located just anterior to the vertebral body, continues superiorly to join the superior vena cava (SST Figure 21-16).

Digestive System

The esophagus (13) continues inferiorly.

Muscular System

See the muscles listed in the previous section. Muscles of the arm surround the humerus.

Nervous System

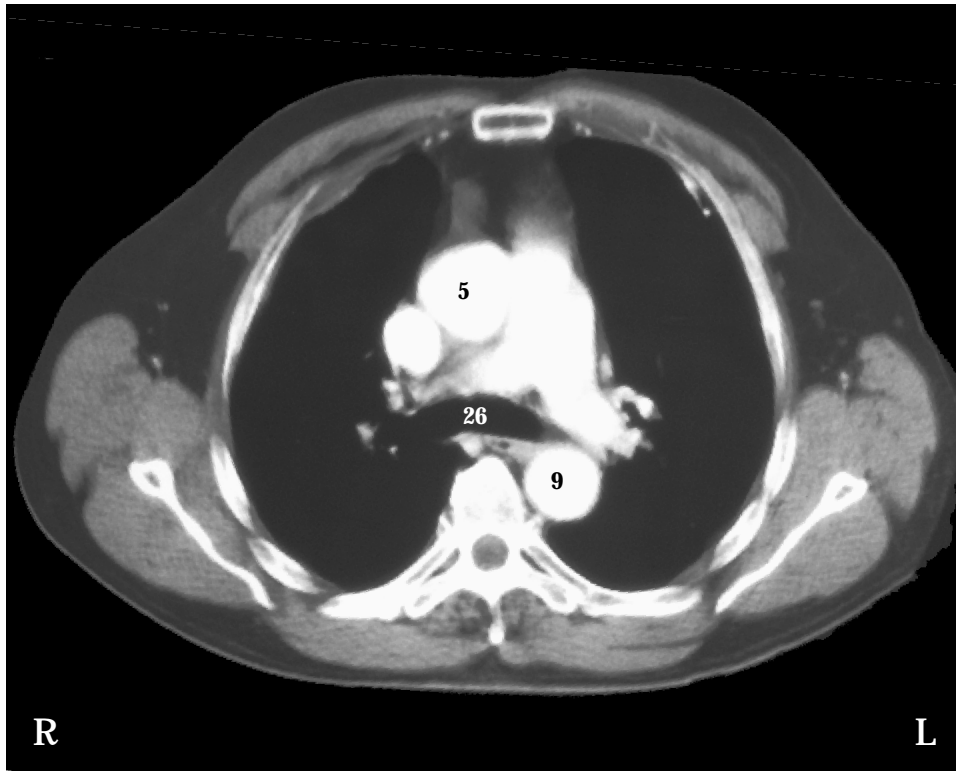
The spinal cord (15) continues inferiorly. Note the spinal nerves (16) exiting the spinal cord (SST Figure 14-2).

Respiratory System

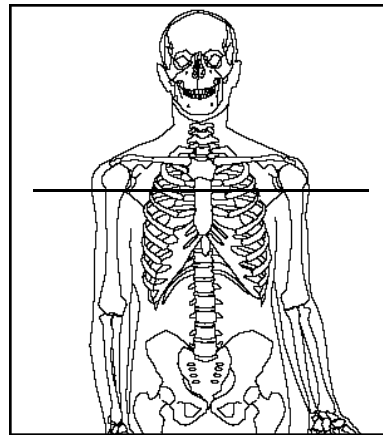
The right lung (22) is larger than the left lung (17). The oblique fissure (18) separates the lobes of the left lung. Right (11) and left (12) primary bronchi are located inferior to their bifurcation from the trachea (SST Figure 23-5, A).

Skeletal System

The scapula (20) and humerus (21) are located bilaterally; the body of the sternum (1) is anterior to the mediastinum (2). Note the thoracic vertebra (14) and ribs (19) (SST Figure 7-19, A).

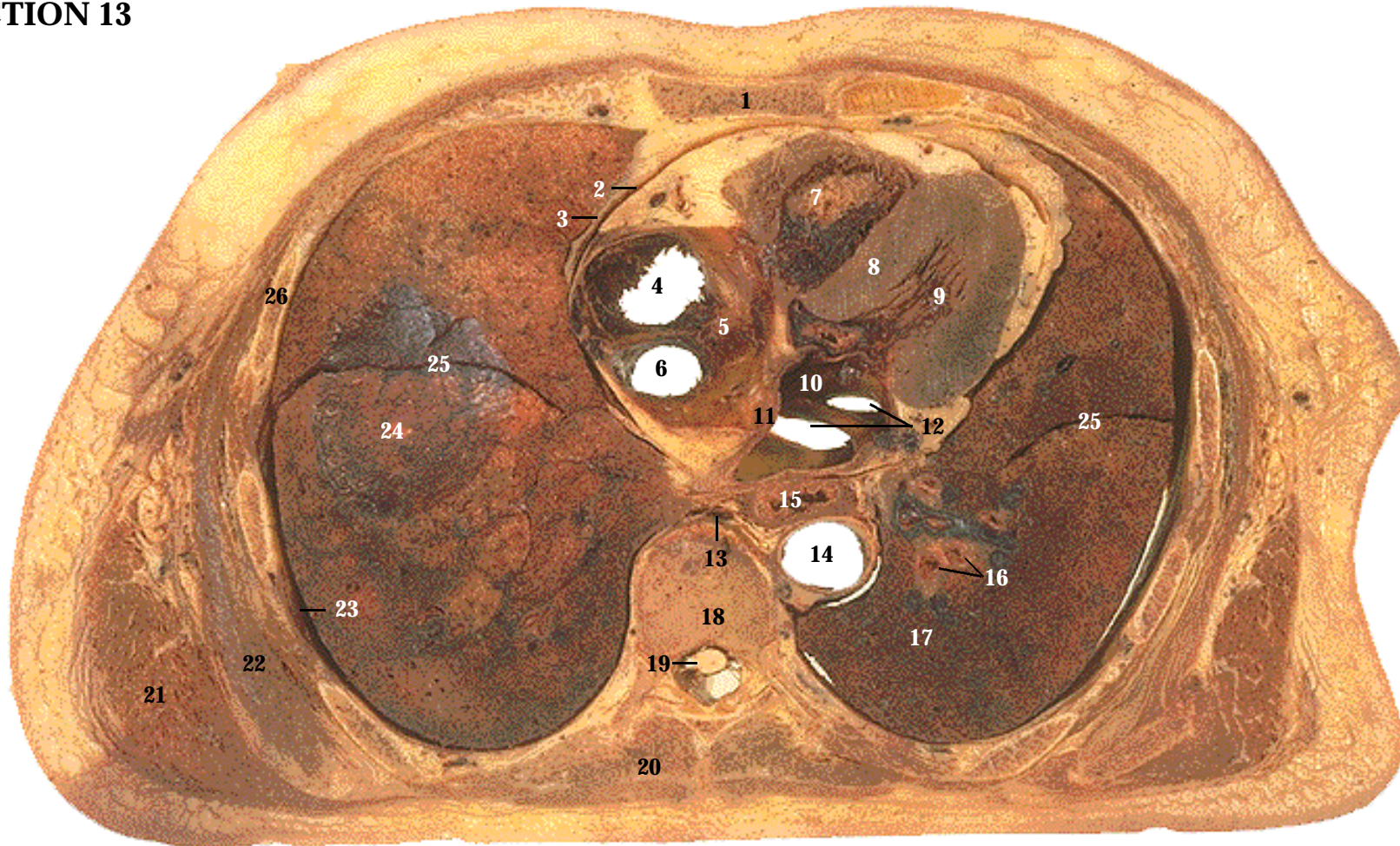


CT image. A classic picture of the pulmonary trunk dividing to form the pulmonary arteries. Together they form an inverted y-shaped structure. The ascending aorta (5) is always anterior to the descending aorta (9), which is located just to the left of the midline along the vertebral body. The trachea (26), which appears black, is dividing to form the right and left primary bronchi. Inferior to this point, the esophagus is located next to the descending aorta.



Level: Through T6. Thorax, through the lungs and pulmonary trunk.

SECTION 12



- | | | |
|------------------------------|---------------------------------|------------------------------|
| 1. Body of sternum | 10. Left atrium | 19. Spinal cord |
| 2. Pericardial cavity | 11. Interatrial septum | 20. Trapezius muscle |
| 3. Pericardial sac | 12. Pulmonary veins | 21. Latissimus dorsi muscle |
| 4. Top of right atrium (cut) | 13. Azygos vein | 22. Serratus anterior muscle |
| 5. Right atrium | 14. Descending (thoracic) aorta | 23. Pleural cavity |
| 6. Superior vena cava | 15. Esophagus | 24. Base of right lung |
| 7. Right ventricle | 16. Bronchi | 25. Oblique fissure |
| 8. Interventricular septum | 17. Left lung | 26. Rib |
| 9. Left ventricle | 18. Body of vertebra | |

Systemic Descriptions

Cardiovascular System

The pericardial sac (3) and pericardial cavity (2) surround the heart (SST Figure 20-4). The superior vena cava (6) enters the right atrium (5) (SST Figure 20-8). The top of the right atrium (4) has been cut, so it appears to be an opening. Pulmonary veins (12) enter the left atrium (10), which is separated from the right atrium by the interatrial septum (11). The interventricular septum (8) separates the right ventricle (7) from the left ventricle (9). Compare the difference in thickness of the walls of the atria, right ventricle, and left ventricle (SST Figure 20-8). The descending (thoracic) aorta (14) continues inferiorly (SST Figure 21-9, B), and the azygos vein (13) continues superiorly (SST Figure 21-16).

Digestive System

The esophagus (15) continues inferiorly.

Muscular System

The latissimus dorsi (21), serratus anterior (22), and trapezius (20) (SST Figure 11-3).

Nervous System

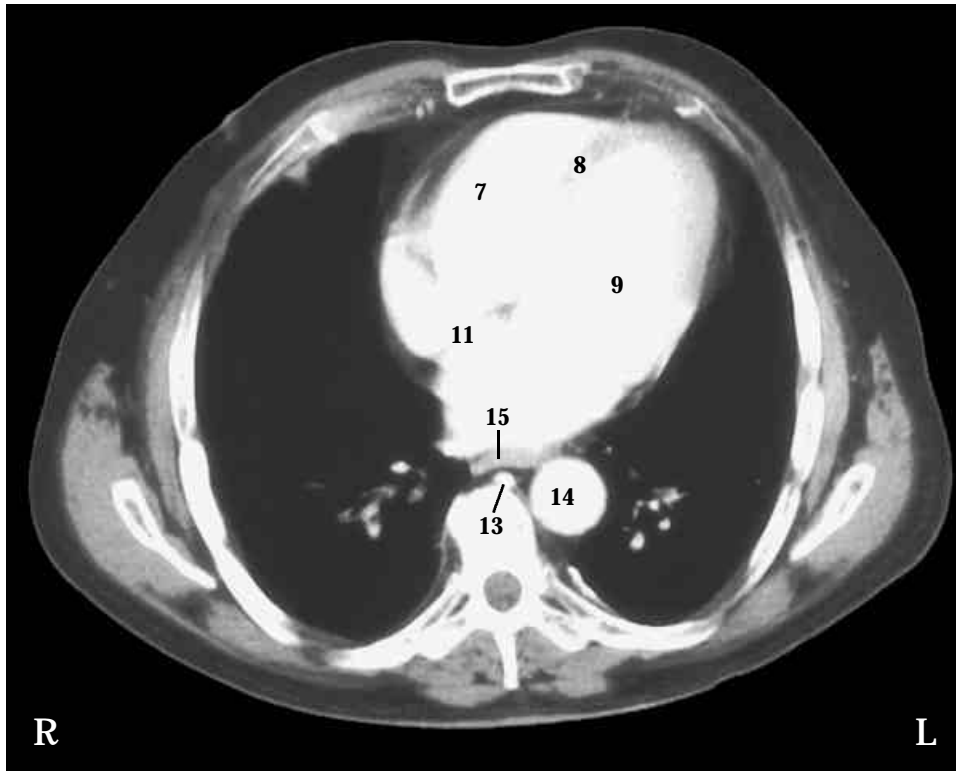
The spinal cord (19) continues inferiorly.

Respiratory System

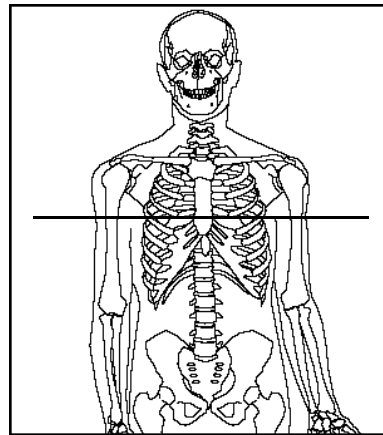
A pleural cavity (23) surrounds each lung (SST Figure 23-7). Oblique fissures (25) divide the left (17) and right (24) lungs into lobes, and bronchi (16) are visible within the lungs (SST Figure 23-6). The concave base of the right lung has been cut, leaving a shallow basin (24). The base of the right lung is at a higher level than the base of the left lung because of the position of the liver on the right side.

Skeletal System

Thoracic vertebra (18), ribs (26), and the body of the sternum (1) are present in this section (SST Figure 7-19, A).

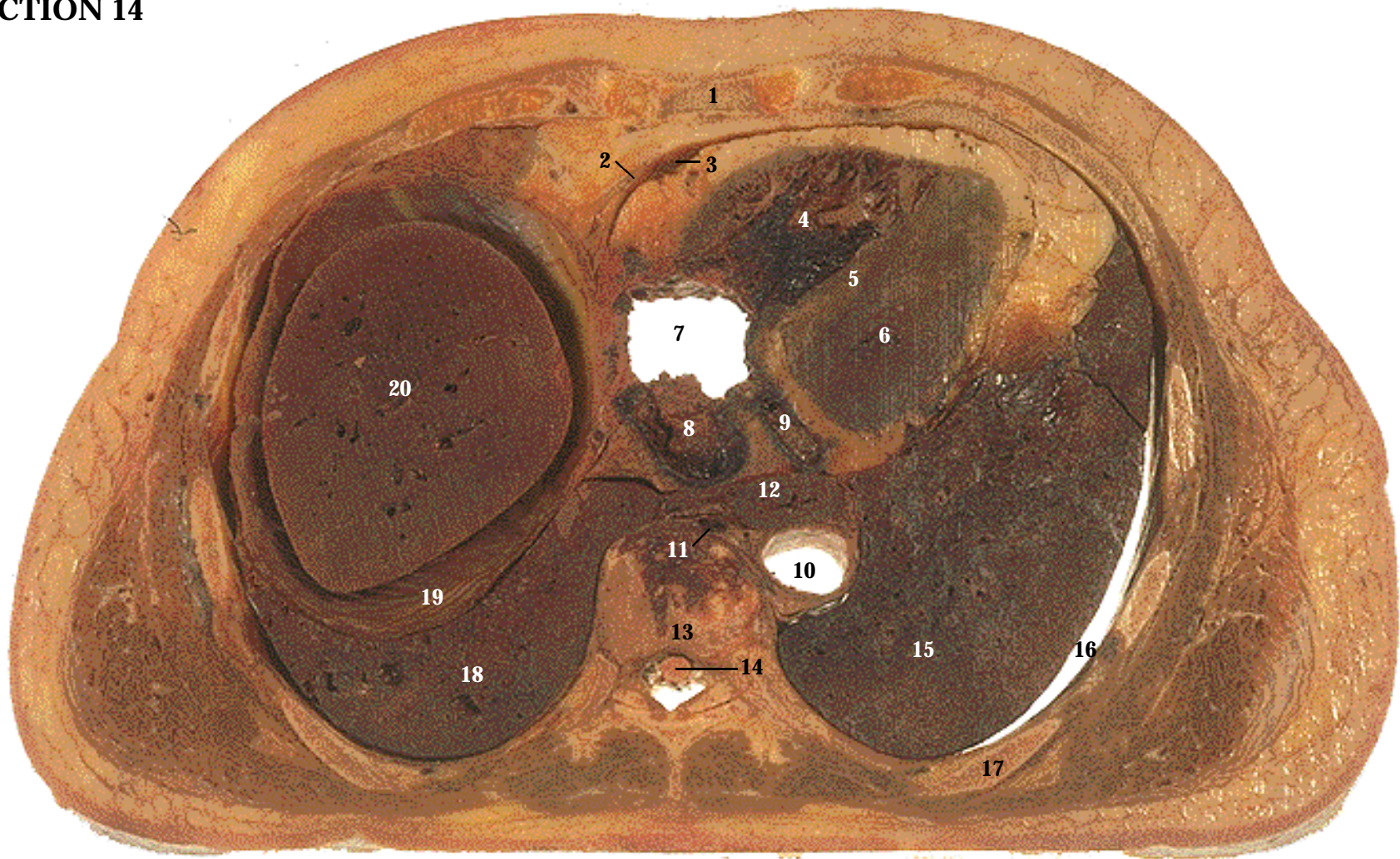


CT image. From anterior to posterior, the esophagus (15), descending aorta (14), and body of vertebra are visible. The azygos vein (13) is located to the right of the descending aorta. The heart appears white because it is filled with contrast media. The four chambers of the heart are visible. The interventricular septum (8) and the interatrial septum (11), which separate the left and right sides of the heart, appear gray. A few pulmonary blood vessels, also filled with contrast media, appear as white spots within the lungs.



Level: Through T8. Thorax, through the lungs and heart.

SECTION 13



- | | | |
|----------------------------|---------------------------------|-------------------------|
| 1. Body of sternum | 9. Coronary sinus | 17. Rib |
| 2. Pericardial sac | 10. Descending (thoracic) aorta | 18. Right lung |
| 3. Pericardial cavity | 11. Azygos vein | 19. Diaphragm |
| 4. Right ventricle | 12. Esophagus | 20. Liver |
| 5. Interventricular septum | 13. Body of vertebra | 21. Bony spur (CT only) |
| 6. Left ventricle | 14. Spinal cord | |
| 7. Right atrium | 15. Left lung | |
| 8. Inferior vena cava | 16. Pleural cavity | |

Systemic Descriptions

Cardiovascular System

The pericardial sac (2) and pericardial cavity (3) surround the heart (SST Figure 20-4). Note the fat associated with the pericardial sac and the surface of the heart. The right ventricle (4) is mostly filled with blood. The interventricular septum (5) and the wall of the left ventricle surround a small part of the left ventricular chamber (6). The blood-filled inferior vena cava (8) and coronary sinus (9) enter the right atrium (7) (SST Figure 20-7, A). The descending aorta (10) continues inferiorly, and the azygos vein (11) continues superiorly (SST Figure 21-16).

Digestive System

The esophagus (12) continues inferiorly. The right lobe of the liver (20) has been cut (SST Figure 24-12, A). It is in contact with the cut diaphragm,

Muscular System

Part of the diaphragm (19) is between the right lung and the liver (SST page 10). See previous section for other muscles.

Nervous System

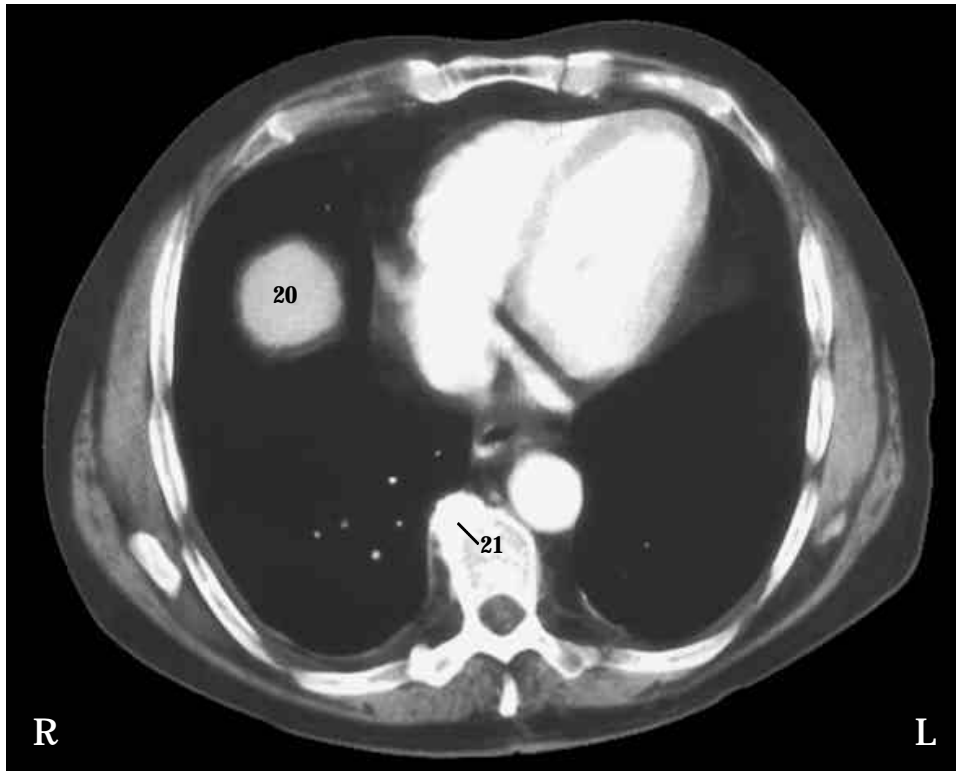
The spinal cord (14) continues inferiorly.

Respiratory System

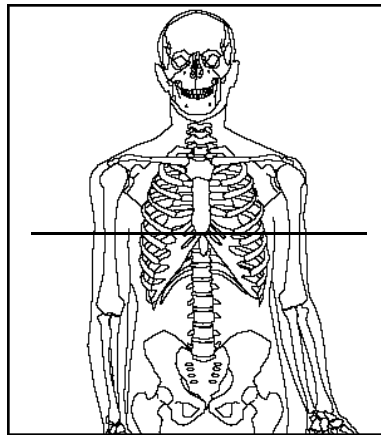
A pleural cavity (16) surrounds each lung (SST Figure 23-7). The right side of the dome-shaped diaphragm has been cut (SST Figure 23-8). This portion of the diaphragm is between the liver and the right lung. The right (18) and left (15) lungs superior to the rest of the diaphragm are also visible.

Skeletal System

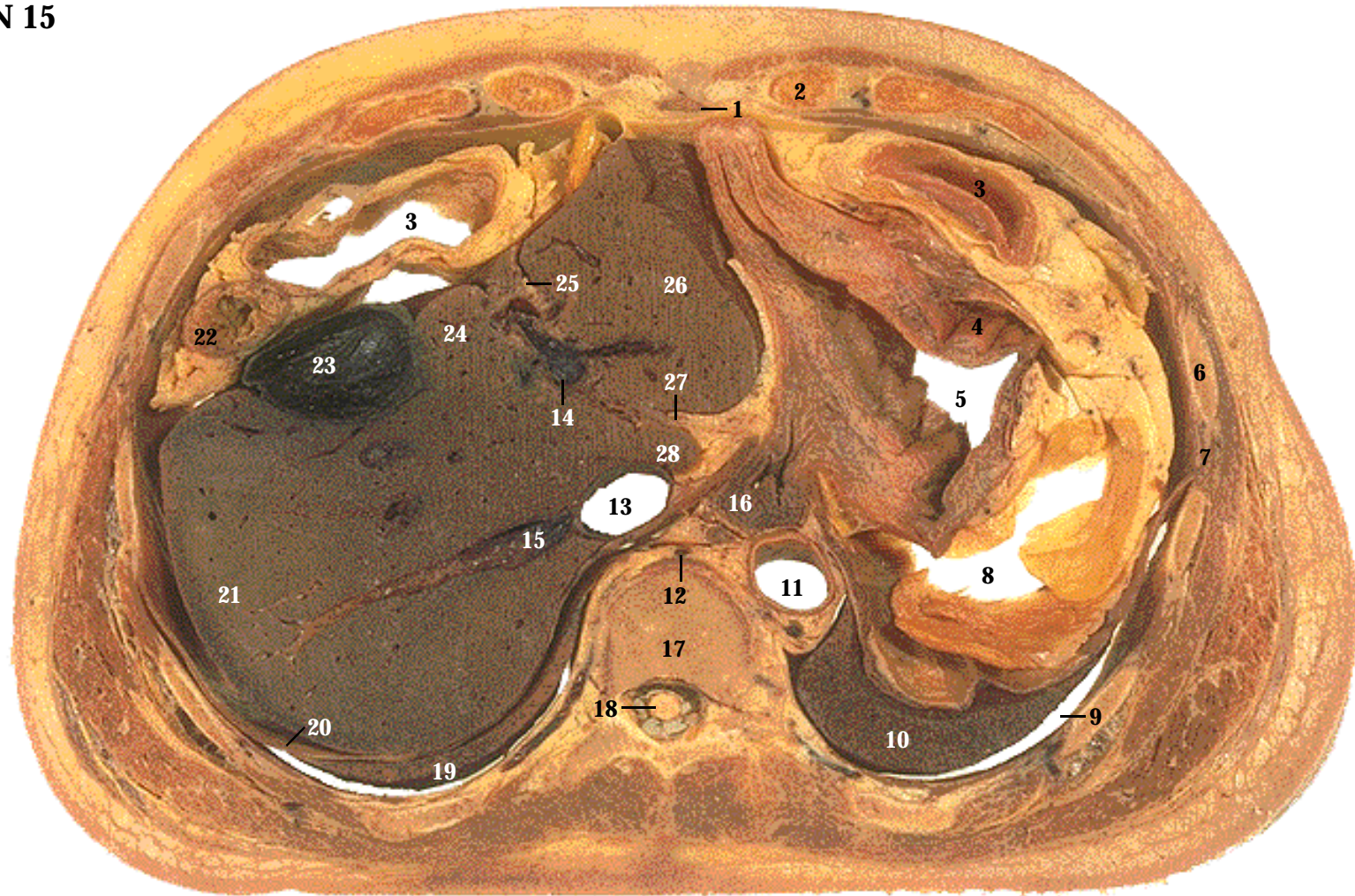
Thoracic vertebra (13), ribs (17), and the body of the sternum (1) are present in this section (SST Figure 7-19, A).



CT image. From anterior to posterior, the esophagus, descending aorta, and body of the vertebra are visible. The azygos vein is located to the right of the descending aorta. A bony spur (21) protrudes from the right side of the vertebral body. Fat within the coronary sulcus appears as a black slash separating the left atrium from the left ventricle.



Level: Through T10. Thorax, through the lungs, heart, and superior part of the liver.



- | | | |
|-------------------------------|----------------------------------|----------------------------|
| 1. Xiphoid process of sternum | 11. Descending (abdominal) aorta | 21. Right lobe of liver |
| 2. Costal cartilage | 12. Azygos vein | 22. Ascending colon |
| 3. Transverse colon | 13. Inferior vena cava | 23. Gallbladder |
| 4. Descending colon | 14. Hepatic portal vein | 24. Quadrate lobe of liver |
| 5. Stomach | 15. Hepatic vein | 25. Falciform ligament |
| 6. Rib | 16. Esophagus | 26. Left lobe of liver |
| 7. Intercostal muscles | 17. Body of vertebra | 27. Ligamentum venosum |
| 8. Peritoneal cavity | 18. Spinal cord | 28. Caudate lobe of liver |
| 9. Pleural cavity | 19. Right lung | 29. Spleen (CT only) |
| 10. Left lung | 20. Diaphragm | |

Systemic Descriptions

Cardiovascular System

The descending (abdominal) aorta (11) and inferior vena cava (13) are next to the esophagus (SST Figure 21-17). The azygos vein (12) continues superiorly (SST Figure 21-16). The hepatic portal vein (14) carries blood to the liver from abdominal organs. One of the hepatic veins (15) empties into the inferior vena cava (SST Figure 21-18). Also note the ligamentum venosum (27), which is a remnant of the fetal ductus venosus (SST Figure 29-19, B).

Digestive System

The esophagus (16) joins the stomach (5) (SST Figure 24-8, A). The ascending (22), transverse (3), and descending (4) colons are present (SST Figure 24-14, A). The ascending colon is usually located just inferior to the liver. In this person, the ascending colon is more superior and anterior to the liver. The transverse colon is cut twice because it hangs inferiorly between the ascending and descending colons (SST Figure 24-14, B). The falciform ligament (25) is between the left (26) and quadrate (24) lobes of the liver. The right (21) and caudate (28) liver lobes are present (Turn SST Figure 24-12, B upside down to see these relationships). The gallbladder (23) is on the anterior surface of the liver (SST Figure 24-13). The space between abdominal organs is the peritoneal cavity (8) (SST Figure 1-15).

Muscular System

The inferior circumference of the diaphragm (20) near its attachment to the thoracic wall (SST Figure 23-8). Note the intercostal muscles (7) between the ribs (6) (SST Figure 11-14).

Nervous System

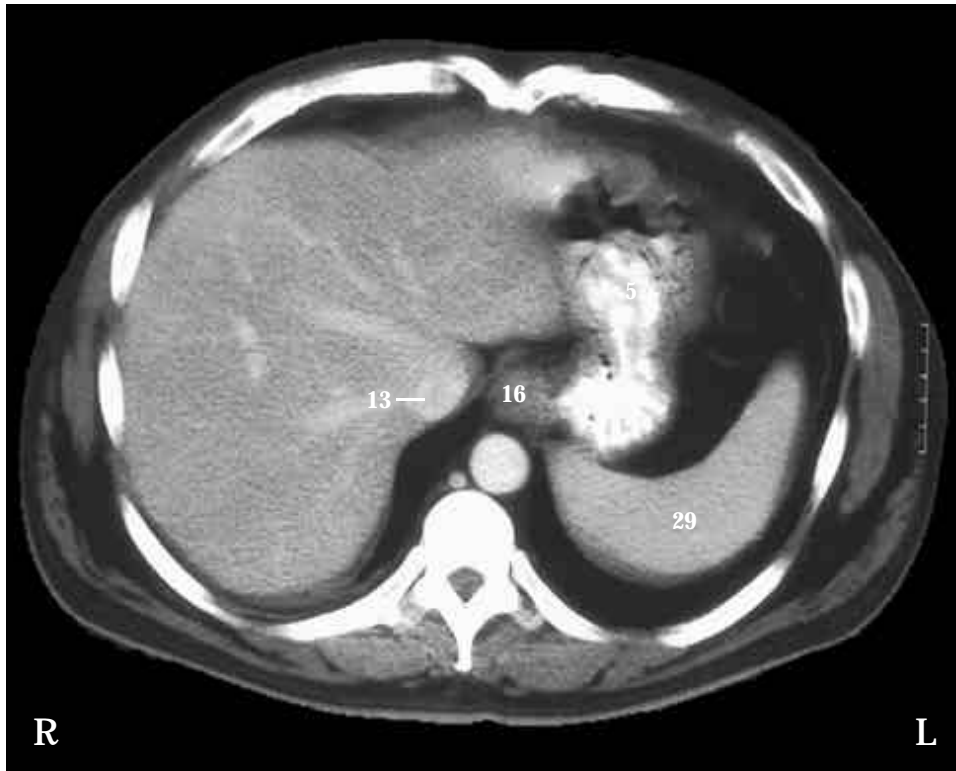The spinal cord (18) continues inferiorly.

Respiratory System

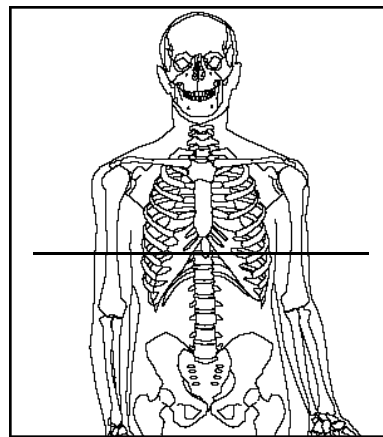
The left (10) and right (19) lungs and the pleural cavity (9).

Skeletal System

Vertebra (17), ribs (6), xiphoid process (1) of the sternum, and costal cartilages (2) (SST Figure 7-19, A).

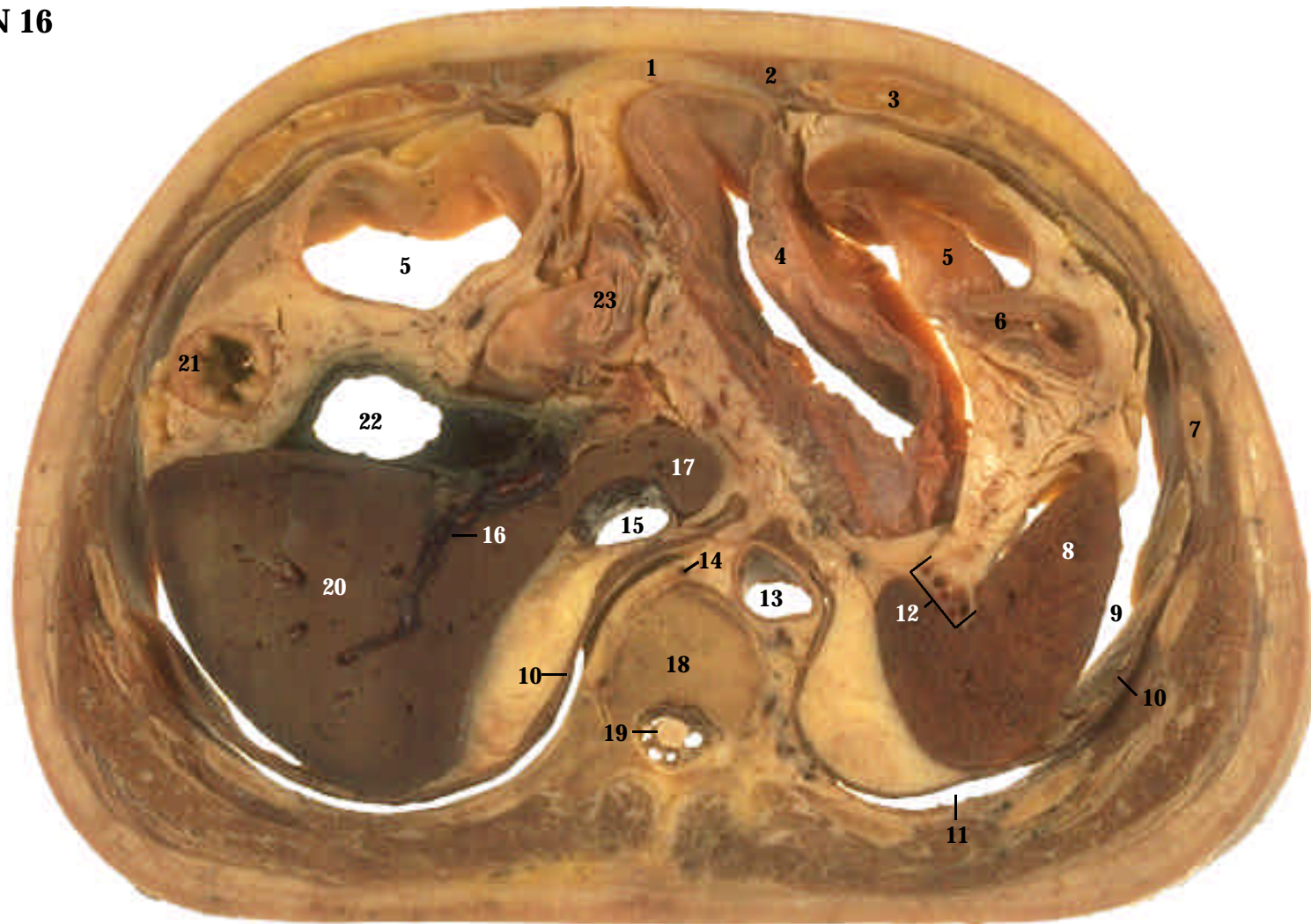


CT image. Oral and intravenous contrast media enhance the GI tract and blood vessels. There is considerable variation in the location of organs within the abdominal cavity. The CT images in Sections 15-18 show the major organs, but are not a perfect match to the cadaver sections. Do not confuse the inferior left lung (10) in the cadaver section with the spleen (29) (SST Figure 22-1 and 22-5) in the CT. Also, the colon (3, 4, and 22) is visible in the cadaver section, but not in the CT.



Level: Through T11.
Abdominal cavity, through the stomach and liver.

SECTION 15



- | | | |
|----------------------|---|----------------------------------|
| 1. Linea alba | 10. Diaphragm | 19. Spinal cord |
| 2. Rectus abdominis | 11. Pleural cavity | 20. Right lobe of liver |
| 3. Costal cartilage | 12. Branches of splenic artery and vein | 21. Ascending colon |
| 4. Body of stomach | 13. Descending (abdominal) aorta | 22. Lumen of gallbladder |
| 5. Transverse colon | 14. Azygos vein | 23. Superior part of duodenum |
| 6. Descending colon | 15. Inferior vena cava | 24. Kidney (CT only) |
| 7. Rib | 16. Branch of hepatic portal vein | 25. Pancreas (CT only) |
| 8. Spleen | 17. Caudate lobe of liver | 26. Adrenal gland (CT only) |
| 9. Peritoneal cavity | 18. Body of vertebra | 27. Falciform ligament (CT only) |

Systemic Descriptions

Cardiovascular System

The descending (abdominal) aorta (13) extends inferiorly, and the inferior vena cava extends superiorly (15). The azygos vein (14) continues superiorly. Branches of the splenic artery and vein (12) are located next to the spleen. A branch of the hepatic portal vein (16) carries blood from abdominal organs into the liver.

Digestive System

The ascending colon (21) continues superiorly, and the descending colon continues inferiorly (6). The transverse colon (5) extends inferiorly on each side of the body of the stomach (4), which also extends inferiorly. The superior part of the duodenum (23) projects upward from Section 17 and extends toward the gallbladder (22), the lumen of which is clearly visible. The superior part of the duodenum then turns inferiorly to form the descending part of the duodenum, which can be seen Section 17 (SST Figure 24-9). The right (20) and caudate (17) lobes of the liver are still present. The space between abdominal organs is the peritoneal cavity (9) (SST Figure 1-15).

Lymphatic System

The spleen (8) (SST Figures 22-1 and 22-5, A).

Muscular System

The rectus abdominis (2) and linea alba (1) continue inferiorly (SST Figure 11-15). The diaphragm (10) extends inferiorly to attach to the lumbar vertebrae.

Nervous System

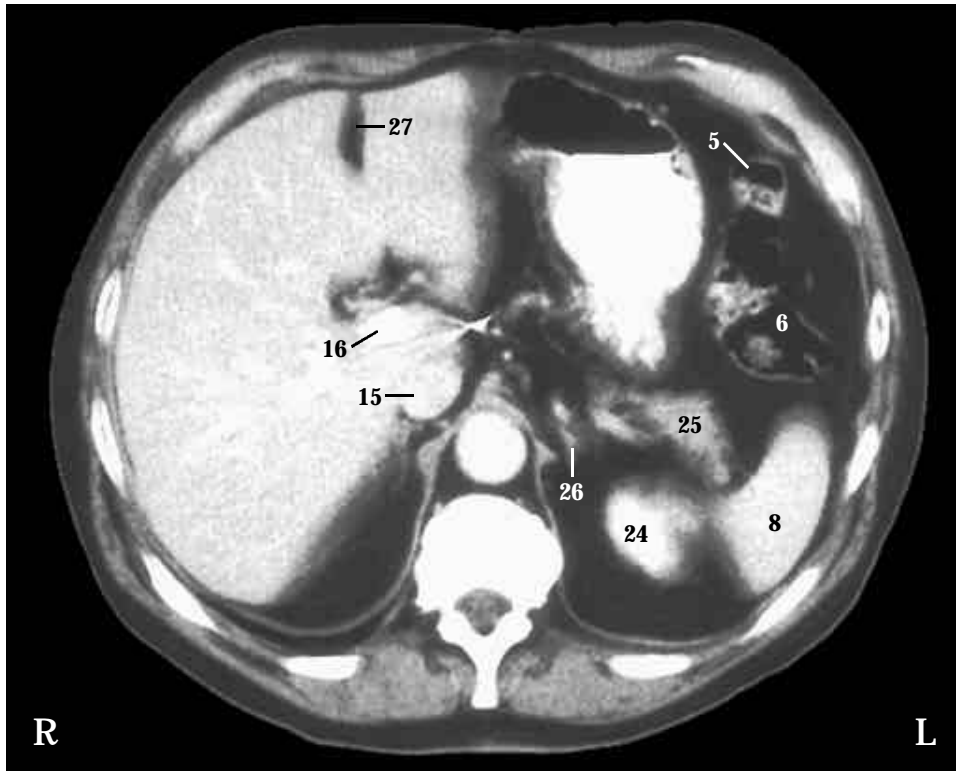
The spinal cord (19) continues inferiorly.

Respiratory System

The inferior part of the pleural cavity (11).

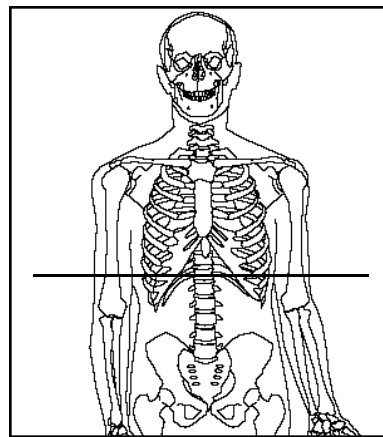
Skeletal System

A lumbar vertebra (18), ribs (7), and costal cartilages (3) are present (SST Fig 7-19, A).

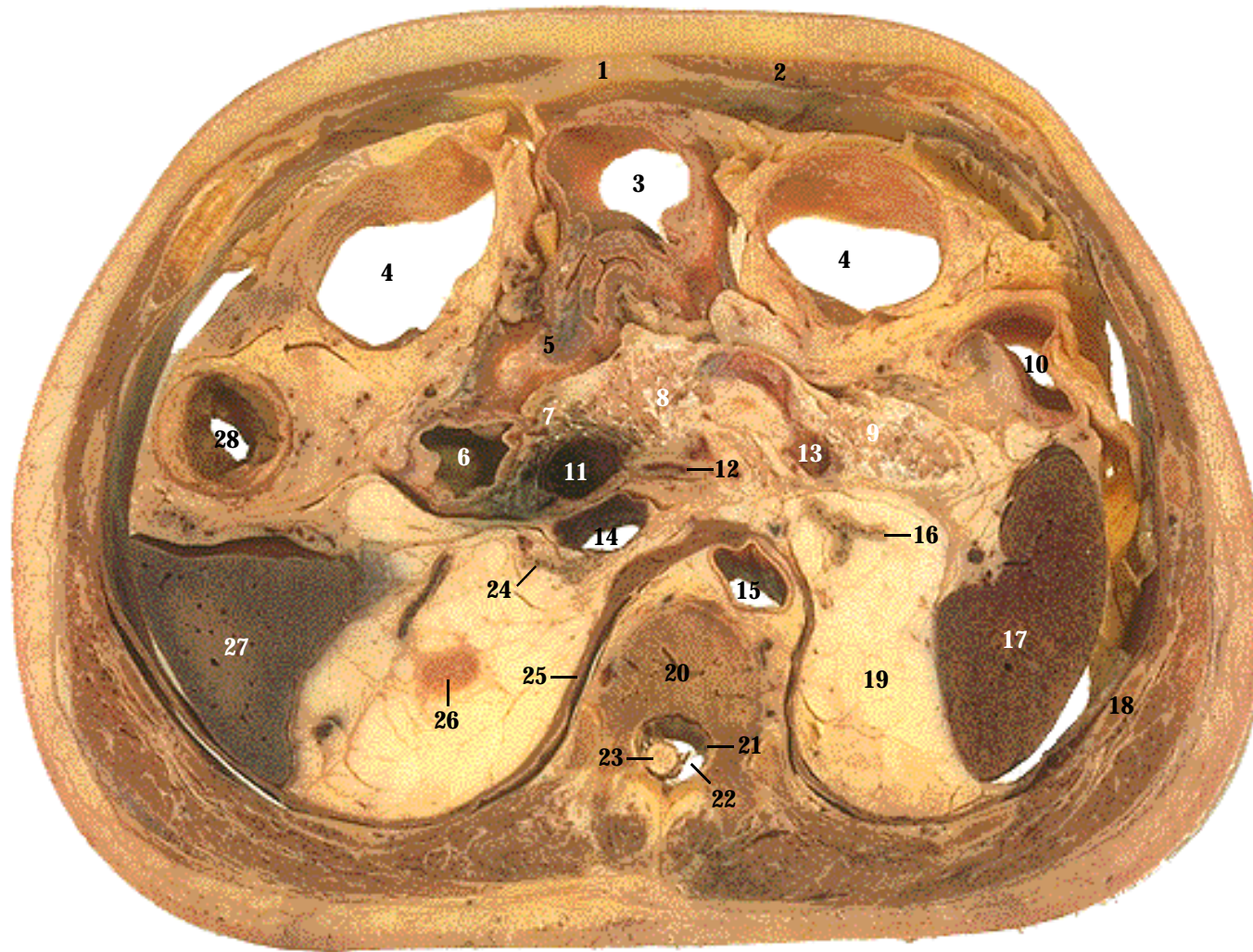


CT image. The stomach, transverse colon (5), descending colon (6), and spleen (8) are seen in both the cadaver and CT. Because the person is lying down, the contrast medium (white) in the stomach forms a level interface with the air (black) in the stomach. The liver in this CT is more like the liver in cadaver Section 15, including the falciform ligament (27) and the hepatic portal vein (16). The pancreas (25) and adrenal gland (26) in this CT can be seen in cadaver Section 17. The kidney (24) in this CT can be seen in cadaver Section 18.

SECTION 16



Level: Through T12.
Abdominal cavity, through the stomach, liver, and spleen.



- | | | |
|--------------------------------|----------------------------------|----------------------------|
| 1. Linea alba | 12. Common hepatic artery | 23. Spinal cord |
| 2. Rectus abdominis muscle | 13. Splenic artery | 24. Right adrenal gland |
| 3. Stomach (pylorus) | 14. Inferior vena cava | 25. Diaphragm |
| 4. Transverse colon | 15. Descending (abdominal) aorta | 26. Kidney |
| 5. Superior part of duodenum | 16. Left adrenal gland | 27. Liver |
| 6. Descending part of duodenum | 17. Spleen | 28. Ascending colon |
| 7. Head of pancreas | 18. Rib | 29. Celiac trunk (CT only) |
| 8. Body of pancreas | 19. Perirenal fat | 30. Splenic vein (CT only) |
| 9. Tail of pancreas | 20. Body of vertebra | 31. Gallbladder (CT only) |
| 10. Descending colon | 21. Dura mater | |
| 11. Hepatic portal vein | 22. Subarachnoid space | |

Systemic Descriptions

Cardiovascular System

The descending (abdominal) aorta (15) and the inferior vena cava (14) are next to the vertebra. The hepatic portal vein (11) (SST Figure 21-18) and common hepatic artery (12) (SST Figure 21-10, A) supply the liver. The splenic artery (13) extends along the pancreas.

Digestive System

The pylorus of the stomach (3) joins the superior part of the duodenum (5), which projects upward (SST Figure 24-8, A). The superior part of the duodenum then turns inferiorly to form the descending part of the duodenum (6) (SST Figure 24-9). The pancreas consists of a head (7), located in the curvature of the duodenum, a body (8), and a tail (9) (SST Figure 24-10, A). The tail of the pancreas extends to the spleen (SST Figure 24-13). Note the ascending (28), transverse (4), and descending (10) colons (SST Figure 24-14, A), and the liver (27).

Endocrine System

The right (24) and left (16) adrenal glands are superior to the kidneys (SST Figure 18-12, A) in Section 18.

Lymphatic System

The spleen (17) (SST Figures 22-1 and 22-5, A).

Muscular System

Rectus abdominis (2), linea alba (1), and diaphragm (25).

Nervous System

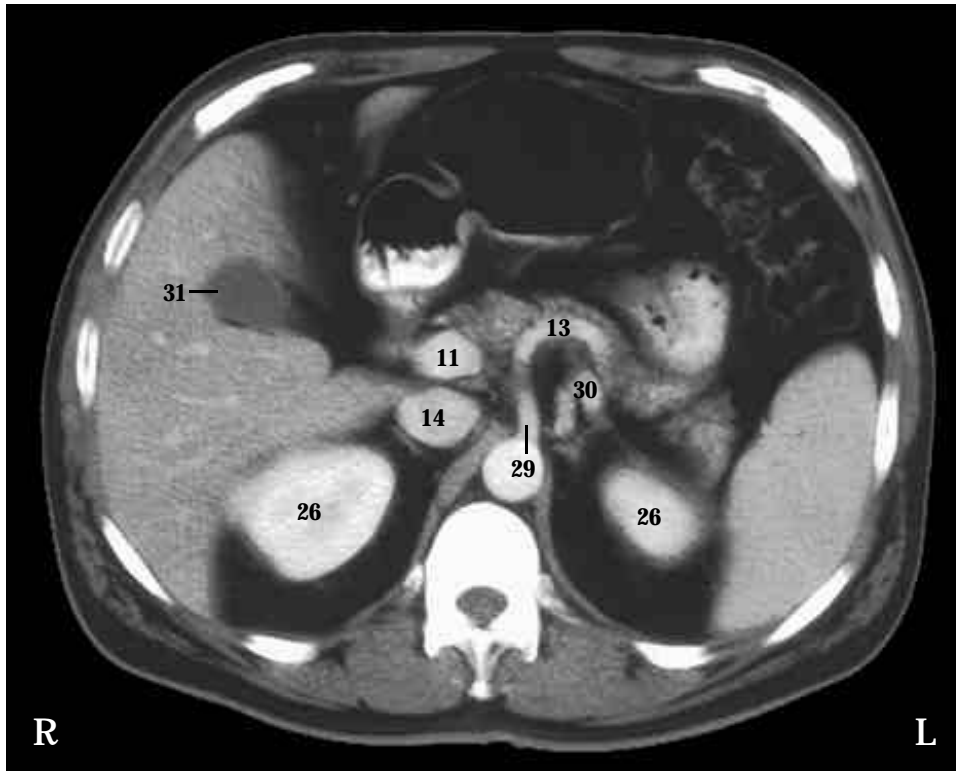
The spinal cord (23) extends inferiorly. The dura mater (21) and subarachnoid space (22) are visible (SST Figure 13-28, B).

Skeletal System

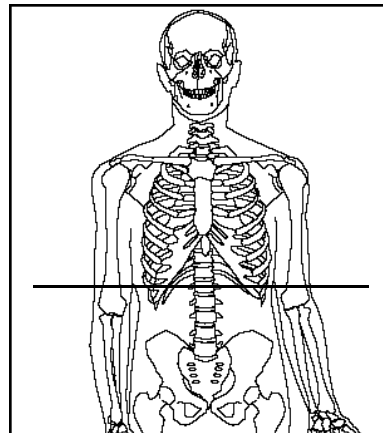
Lumbar vertebra (20) and ribs (18) (SST Fig 7-19, A).

Urinary System

Note the perirenal fat (19). The top of the right kidney (26) is barely cut (SST Figure 26-1).

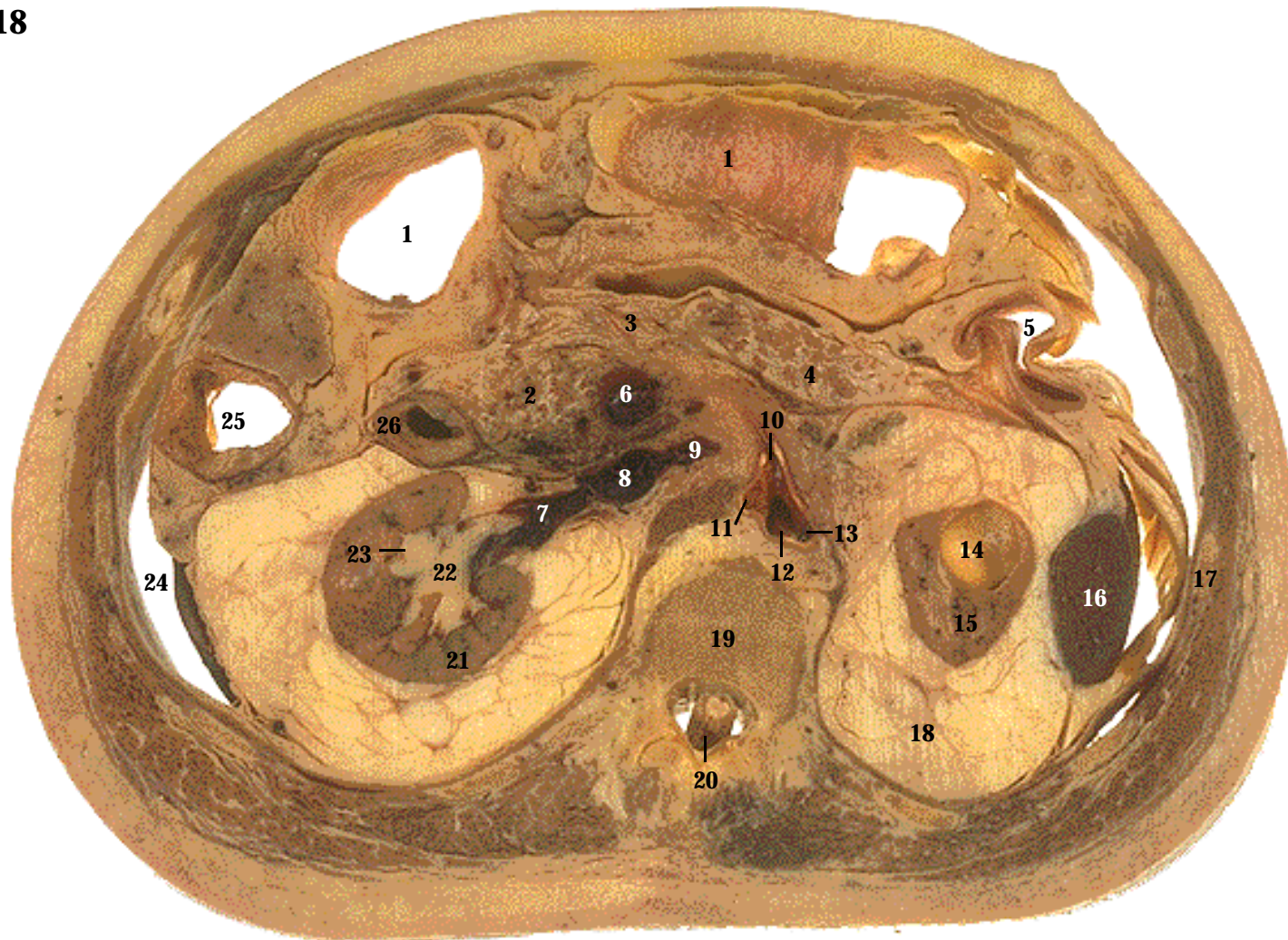


CT image. The pyloric region of the stomach joins the superior part of the duodenum in both the CT and cadaver sections. In the CT, the celiac trunk (29) branches from the aorta and gives rise to the splenic artery (13). The splenic vein (30) is posterior to the splenic artery. The kidneys (26) in this CT can be seen in cadaver Section 18, and the gallbladder (31) in Section 16.



Level: Through L1.
Abdominal cavity, through the stomach, pancreas, and spleen.

SECTION 17



- | | | |
|--------------------------------|----------------------------------|---------------------------------|
| 1. Transverse colon | 11. Right renal artery | 21. Right kidney |
| 2. Head of pancreas | 12. Descending (abdominal) aorta | 22. Renal pelvis |
| 3. Body of pancreas | 13. Left renal artery | 23. Renal calyx |
| 4. Tail of pancreas | 14. Cyst | 24. Peritoneal cavity |
| 5. Descending colon | 15. Left kidney | 25. Ascending colon |
| 6. Superior mesenteric vein | 16. Spleen | 26. Descending part of duodenum |
| 7. Right renal vein | 17. Rib | 27. Liver (CT only) |
| 8. Inferior vena cava | 18. Perirenal fat | 28. Ureter (CT only) |
| 9. Left renal vein | 19. Body of vertebra | 29. Jejunum (CT only) |
| 10. Superior mesenteric artery | 20. Cauda equina | |

Systemic Descriptions

Cardiovascular System

The descending (abdominal) aorta (12) gives rise to the superior mesenteric artery (10) and the right (11) and left (13) renal arteries (SST Figure 21-9, A). The right (7) and left (9) renal veins enter the inferior vena cava (8) (SST Figure 21-17). The superior mesenteric vein (6) extends superiorly (SST Figure 21-18).

Digestive System

The ascending (25), transverse (1), and descending (5) colons are present (SST Figure 24-14, A). The transverse colon has been obliquely cut. The head (2), body (3), and tail (4) of the pancreas (3) and the descending part of the duodenum (26) are also present (SST Figure 24-10, A). The peritoneal cavity (24) is visible (SST Figure 1-15)

Muscular System

See previous section for muscles.

Lymphatic System

A small portion of the spleen (16) is present posterolaterally on the left side (SST Figure 22-1).

Nervous System

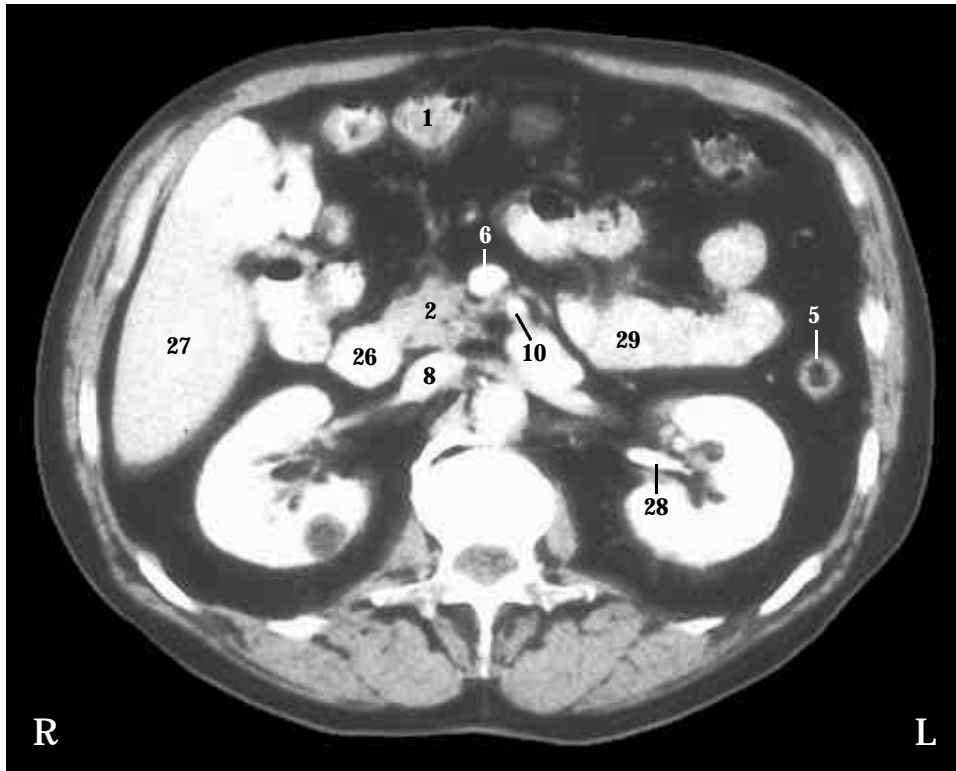
The cauda equina (20) arises from the spinal cord and extends inferiorly through the vertebral canal (SST Figure 13-18).

Skeletal System

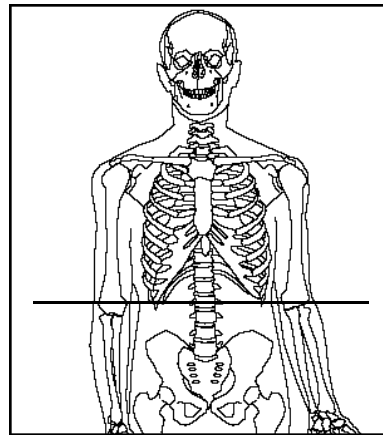
A lumbar vertebra (19) and ribs (17) are present (Fig 7-19, A).

Urinary System

In the right kidney (21), renal calyces (23) and the renal pelvis (22) are evident (SST Figure 26-2). Note the cyst (14) in the left kidney (15), and the thick periremal fat (18) surrounding both kidneys.

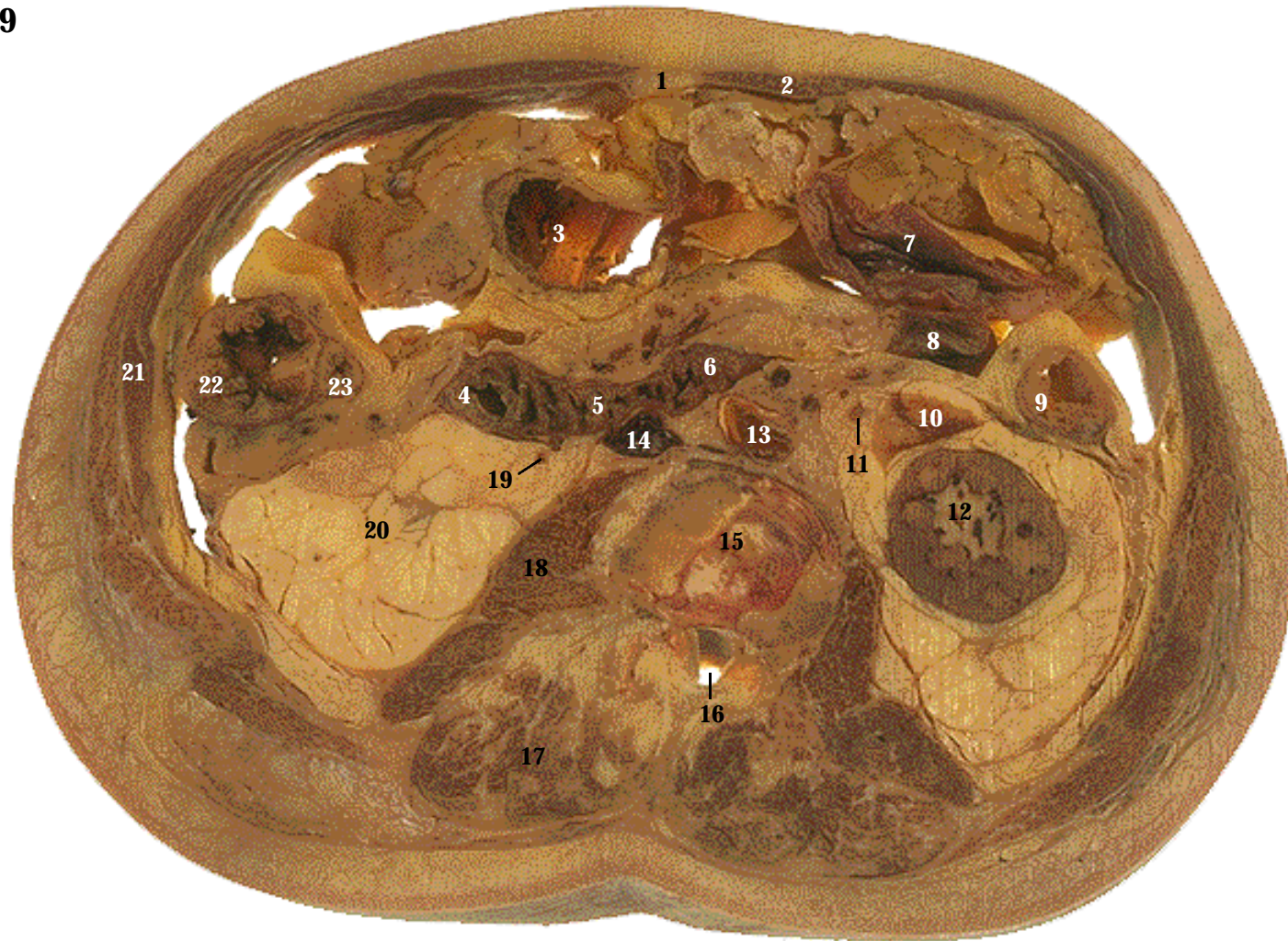

CT image. The left and right renal veins enter the inferior vena cava (8). Note the contrast medium in the left ureter (28). The contrast medium, which is injected into the blood in order to visualize the blood vessels, is removed from the blood by the kidneys. In the CT, the inferior part of the liver (27) is visible, much as in cadaver Section 17. The CT also shows more small intestine (29), which is more like cadaver Section 19. There is a cyst in the right kidney (dark area).



Level: Through L2.
Abdominal cavity through the colon, pancreas, and kidneys.

SECTION 18



- | | | |
|--------------------------------|----------------------------------|----------------------------|
| 1. Linea alba | 9. Descending colon | 17. Erector spinae muscles |
| 2. Rectus abdominis | 10. Cyst | 18. Psoas major muscle |
| 3. Transverse colon | 11. Left ureter | 19. Right ureter |
| 4. Descending part of duodenum | 12. Left kidney | 20. Perirenal fat |
| 5. Horizontal part of duodenum | 13. Descending (abdominal) aorta | 21. Lateral abdominal wall |
| 6. Ascending part of duodenum | 14. Inferior vena cava | 22. Ascending colon |
| 7. Superior loop of jejunum | 15. Intervertebral disk | 23. Ileum |
| 8. Jejunum | 16. Vertebral canal | |

Systemic Descriptions

Cardiovascular System

The descending (abdominal) aorta (13) continues inferiorly and the inferior vena cava (14) continues superiorly.

Digestive System

The descending part of the duodenum (4) turns to the left to form the horizontal part of the duodenum (5). The horizontal part extends to the descending aorta and turns superiorly to form the ascending part of the duodenum (6), which projects superiorly to join the jejunum. The jejunum (8) then extends inferiorly (SST Figure 24-9 and 24-10, A). A loop of the jejunum (7) from a lower level also extends into this section. Note the extensive circular folds in the duodenum (SST Figure 24-11, A). The ascending (22), transverse (3), and descending (9) colons are present. Part of the ileum (23) is seen next to the ascending colon (SST Figure 24-9).

Muscular System

The linea alba (1), rectus abdominis (2) and lateral abdominal wall muscles (21) are present (SST Figure 11-15). The psoas major (18) (SST Figure 11-29, A) and the erector spinae (17) (SST Figure 11-13) are visible.

Nervous System

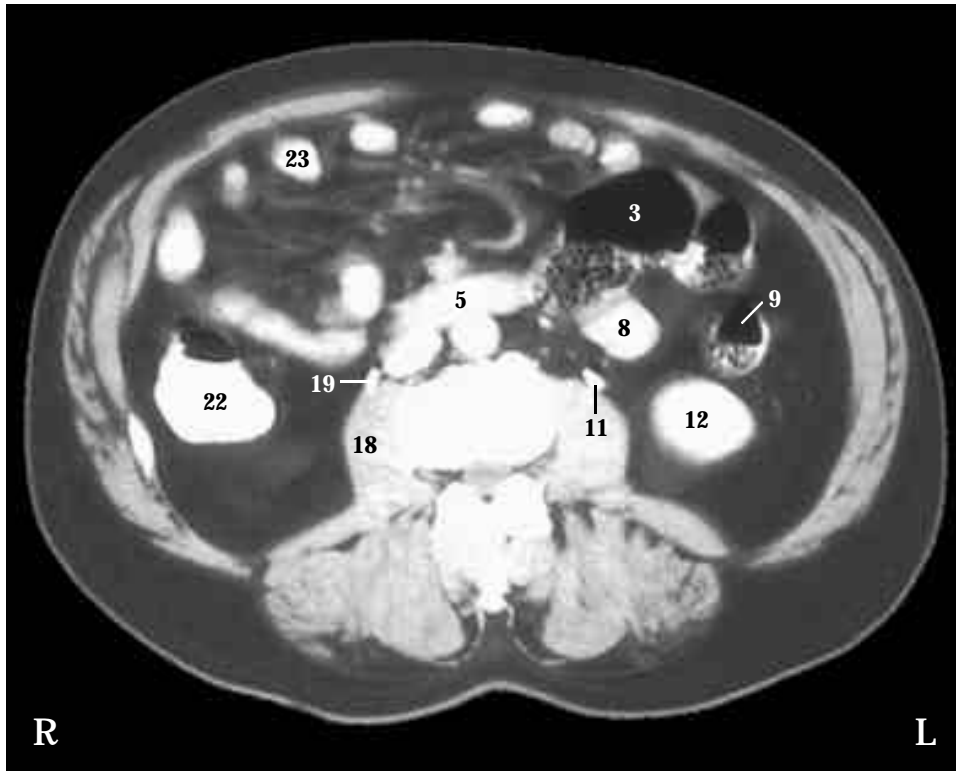
The cauda equina should be present, but is missing from the vertebral canal of this section.

Skeletal System

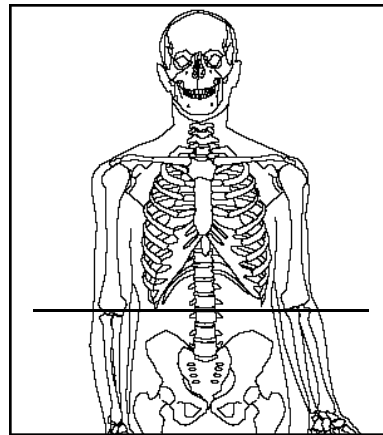
This section is inferior to the ribs. An intervertebral disk (15) and the vertebral canal (16) are cut (SST Figure 7-15, A)

Urinary System

The left kidney (12) is visible, but this section is inferior to the right kidney. Only the perirenal fat (20) is seen on the right. Typically the right kidney is lower than the left (SST Figure 26-1, A), but in this individual the opposite is true. The left (11) and right (19) ureters descend toward the urinary bladder. A cyst (10) is located in the left renal fat pad.

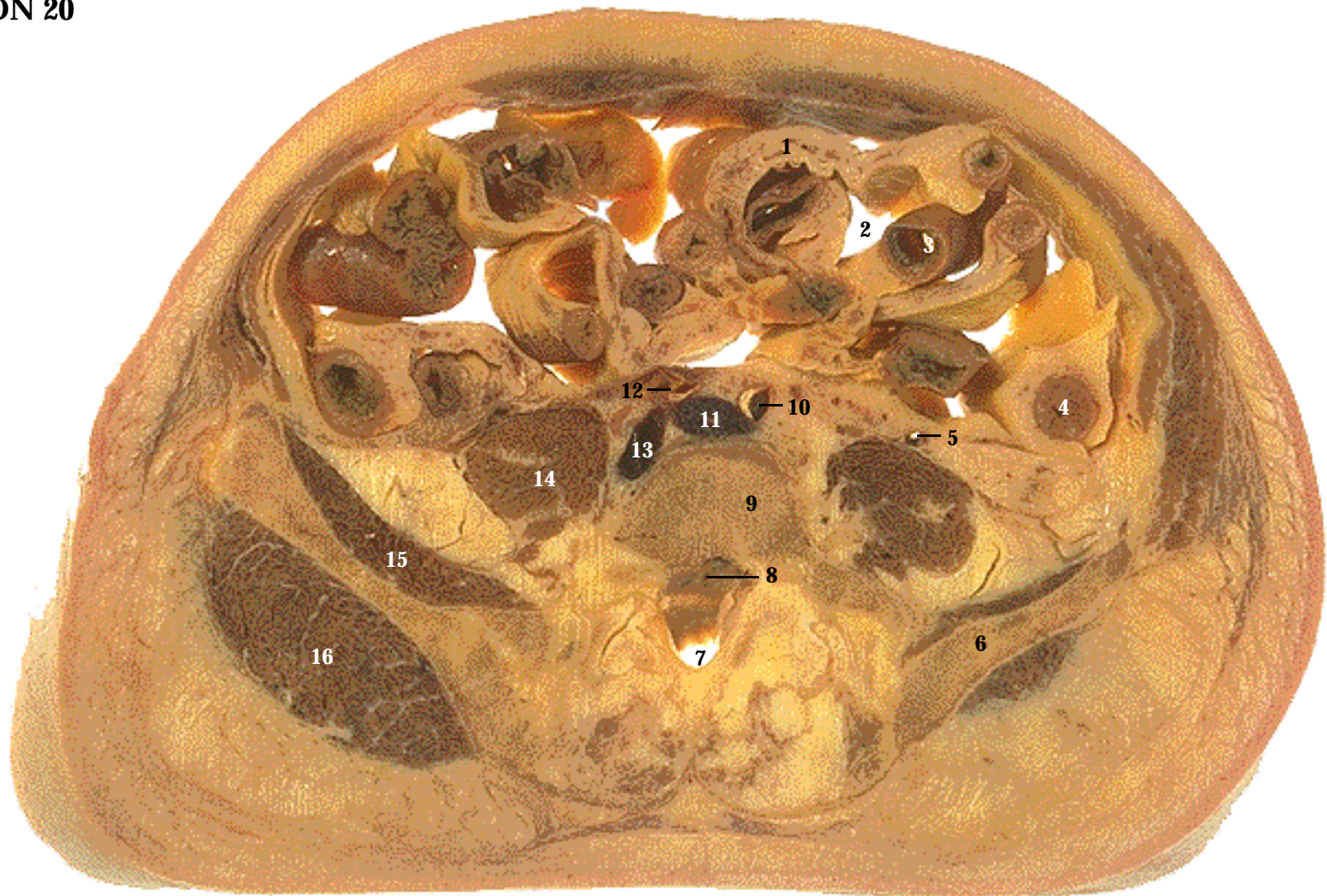


CT image. The psoas major muscles (18) are landmarks used to find the smaller ureters (11 and 19), which are filled with intravenous contrast medium. The oral contrast medium used to enhance the digestive tract has been moved inferiorly by peristalsis. Many loops of the ileum are visible in the CT, but only one loop of the ileum is visible in the cadaver section. Note that the air-filled spaces of the digestive tract appear black.



Level: Intervertebral disk between L2 and L3. The kidney, colon, and small intestine.

SECTION 19



1. Mesentery proper
2. Peritoneal cavity
3. Small intestine
4. Descending colon
5. Ureter
6. Ilium

7. Sacral canal
8. Vertebral canal
9. Body of vertebra
10. Left common iliac artery
11. Left common iliac vein
12. Right common iliac artery

13. Right common iliac vein
14. Psoas major muscle
15. Iliacus muscle
16. Gluteus medius muscle
17. Cecum (CT only)
18. Ileum (CT only)

Systemic Descriptions

Cardiovascular System

The descending (abdominal) aorta has divided to form the left (10) and right (12) common iliac arteries (SST Figure 21-9, A). Note the atherosclerotic plaque associated with the iliac arteries. The left (11) and right (13) common iliac veins are inferior to the location where they join to form the inferior vena cava (SST Figure 21-17).

Digestive System

The descending (4) colon is present, but this section is inferior to the transverse colon (SST Figure 24-14, B). Typically, the ascending colon would be seen on the right side at this level. However, in this individual, structures on the right side are more superior than usual. The mesentery proper (1) holds loops of the small intestine (3) in place within the peritoneal cavity (2) (SST Figure 24-16).

Muscular System

The psoas major muscles (14) are located lateral to the vertebral body and the iliacus muscles (15) are on the medial surface of the ilium (SST Figure 11-29, A). The gluteus medius muscles (16) are on the lateral surface of the ilium (SST Figure 11-28, A).

Nervous System

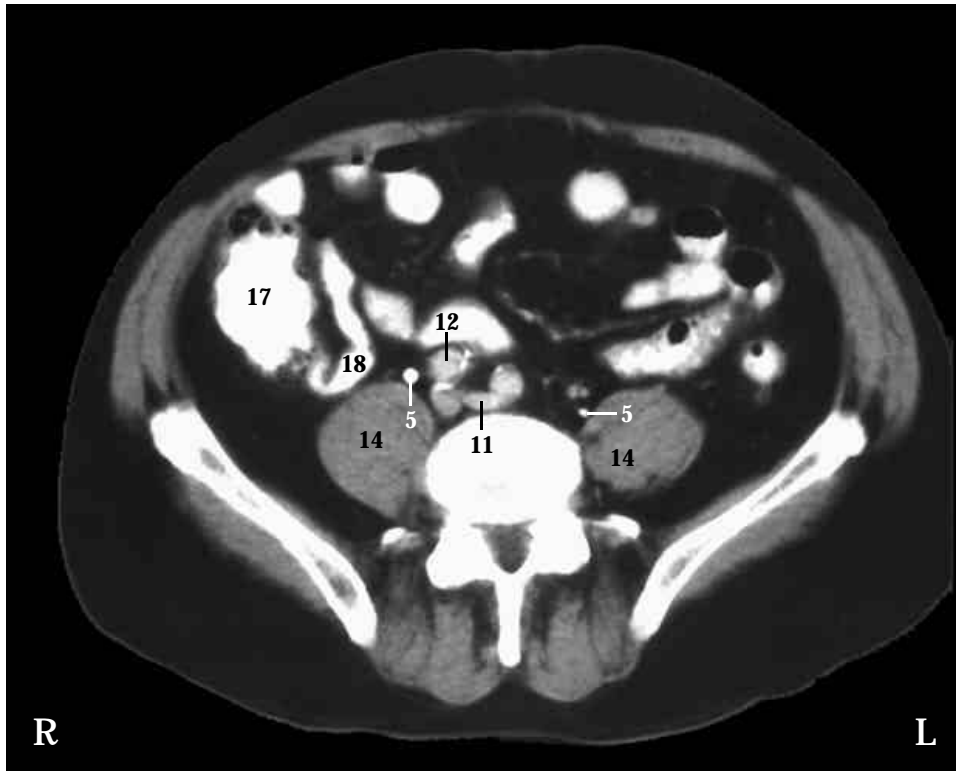The cauda equina should be present, but is missing from this section.

Skeletal System

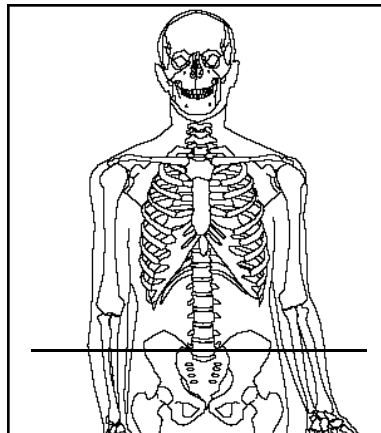
The superior part of the ilium (6) (SST Figure 7-1 and 7-26). The superior part of the opening posterior to the body (9) of the fifth lumbar vertebra is the vertebral canal (8). The inferior part of this opening is the beginning of the sacral canal (7).

Urinary System

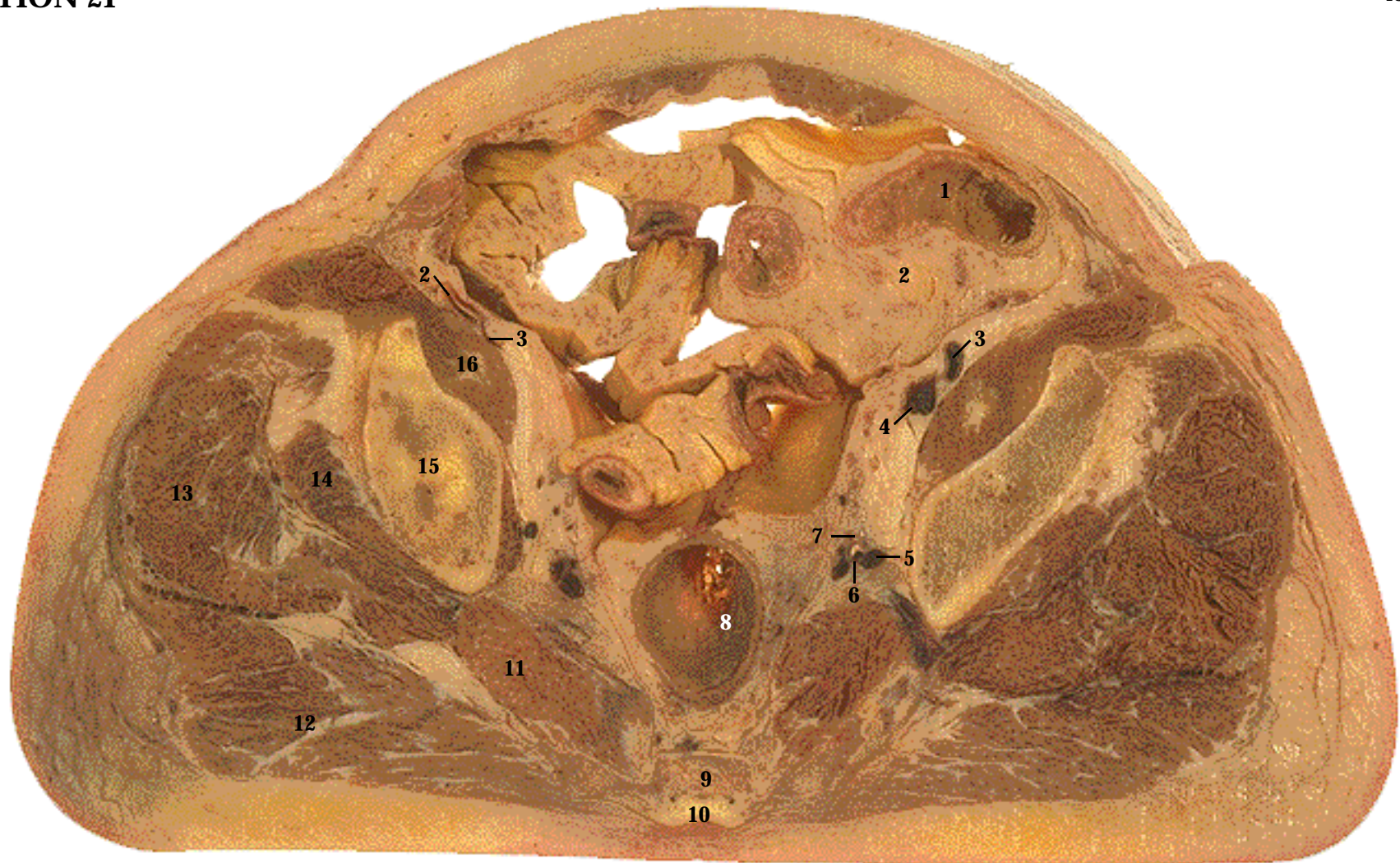The ureters (5) extend from the kidneys to the urinary bladder (SST Figure 26-1, A). The ureters are located just anterior to the psoas major muscles.



CT image. The contrast-filled ureters (5) descend inferiorly with the psoas major muscles (14). The common iliac arteries branch off the descending aorta and extend inferiorly, whereas the common iliac veins extend superiorly to join the inferior vena cava. Seen only in the CT, the ileum (18) joins the cecum (17).



Level: Body of L5 and the superior part of the ilium. The inferior abdominal cavity.



1. Small intestine
2. Mesentery proper
3. External iliac artery
4. External iliac vein
5. Internal iliac vein
6. Internal iliac artery
7. Ureter

8. Rectum
9. Body of sacral vertebra
10. Sacral canal
11. Piriformis muscle
12. Gluteus maximus muscle
13. Gluteus medius muscle
14. Gluteus minimus muscle

15. Ilium
16. Iliopsoas muscle
17. Sigmoid colon (CT only)
18. Urinary bladder (CT only)
19. Ureter (CT only)

Systemic Descriptions

Cardiovascular System

The common iliac arteries branch to form the external iliac arteries (3) and the internal iliac arteries (6). The external iliac arteries project from the posterior abdominal wall toward the lower limbs, and the internal iliac arteries extend to the pelvic cavity (SST Figure 21-9, A). Note the calcification within the left internal iliac artery. The external iliac veins (4) and internal iliac veins (5) are inferior to where they join the common iliac veins (SST Figure 21-17). The external iliac veins return from the lower limbs to the posterior abdominal wall, and the internal iliac veins return from the pelvic cavity.

Digestive System

Part of the small intestine (1), mesentery proper (2), and the rectum (8) are visible (SST Figure 24-9 and 24-14, A).

Muscular System

The iliacus and psoas major muscles converge to form the iliopsoas muscle (16) (SST Figure 11-29, A). Note also the gluteus maximus (12), gluteus medius (13), gluteus minimus (14), and piriformis muscles (11) (SST Figure 11-28).

Nervous System

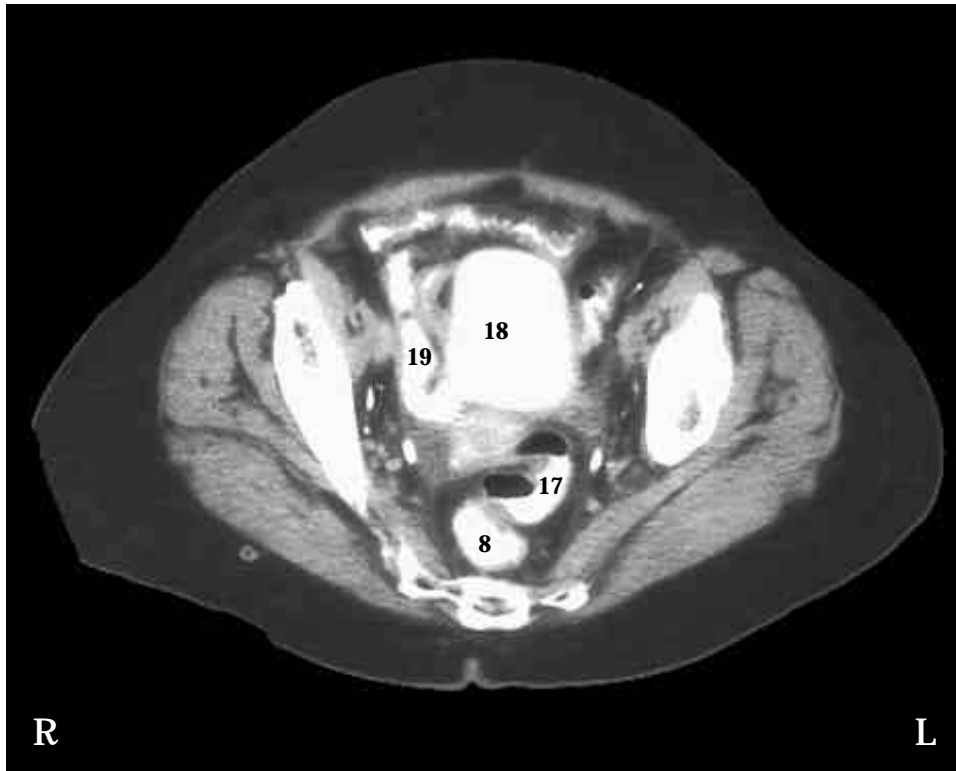
Sacral nerves from the cauda equina continue inferiorly within the sacral canal, but are not easily seen in this section because of surrounding connective tissue.

Skeletal System

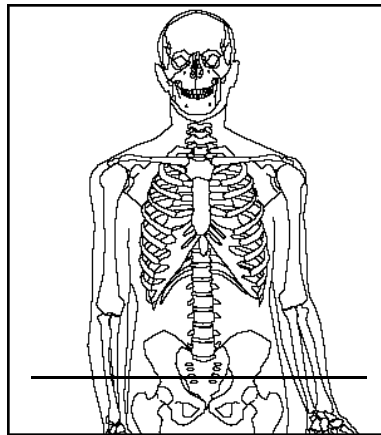
The ilium (15) of each coxa and the body of a sacral vertebra (9) are evident (SST Figure 7-26). The sacral canal (10) is mostly filled with fat and connective tissue (SST Figure 7-18, F).

Urinary System

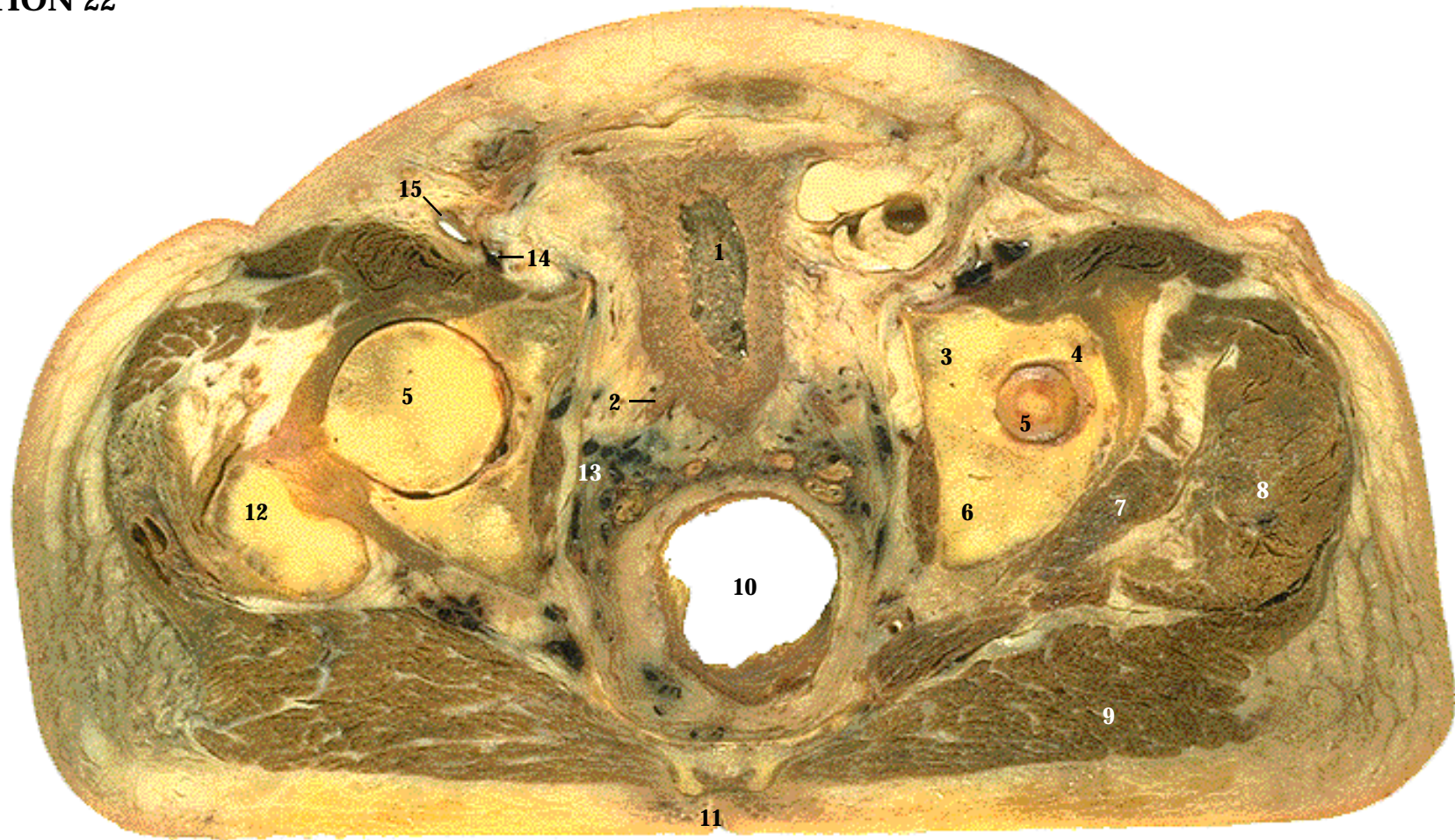
The ureters (7) continue inferiorly (SST Figure 26-1, A).



CT image. The descending colon gives rise to the sigmoid colon, which forms an s-shaped loop to join the rectum. The sigmoid colon (17) can be seen along the midline just before it joins the rectum (8). This CT also shows the urinary bladder (18) with the right ureter (19). To see the urinary bladder and ureter in the cadaver, see Section 22.



Level: Through the sacrum at S3. Pelvic cavity, through the rectum.



1. Urinary bladder
2. Ureter
3. Pubis
4. Ilium
5. Head of femur
6. Ischium

7. Gluteus minimus
8. Gluteus medius
9. Gluteus maximus
10. Rectum
11. Sacral hiatus
12. Greater trochanter

13. Prostatic venous plexus
14. External iliac vein
15. External iliac artery
16. Seminal vesicle (CT only)

Systemic Descriptions

Cardiovascular System

The external iliac arteries (15) continue toward the lower limbs, and the external iliac veins (14) return from the lower limbs (SST Figure 21-11 and 21-19). The prostatic venous plexus (13) is a network of vessels that drains blood from the penis, urinary bladder and prostate gland into the internal iliac vein.

Digestive System

The rectum (10) continues inferiorly (SST Figure 24-14, A).

Muscular System

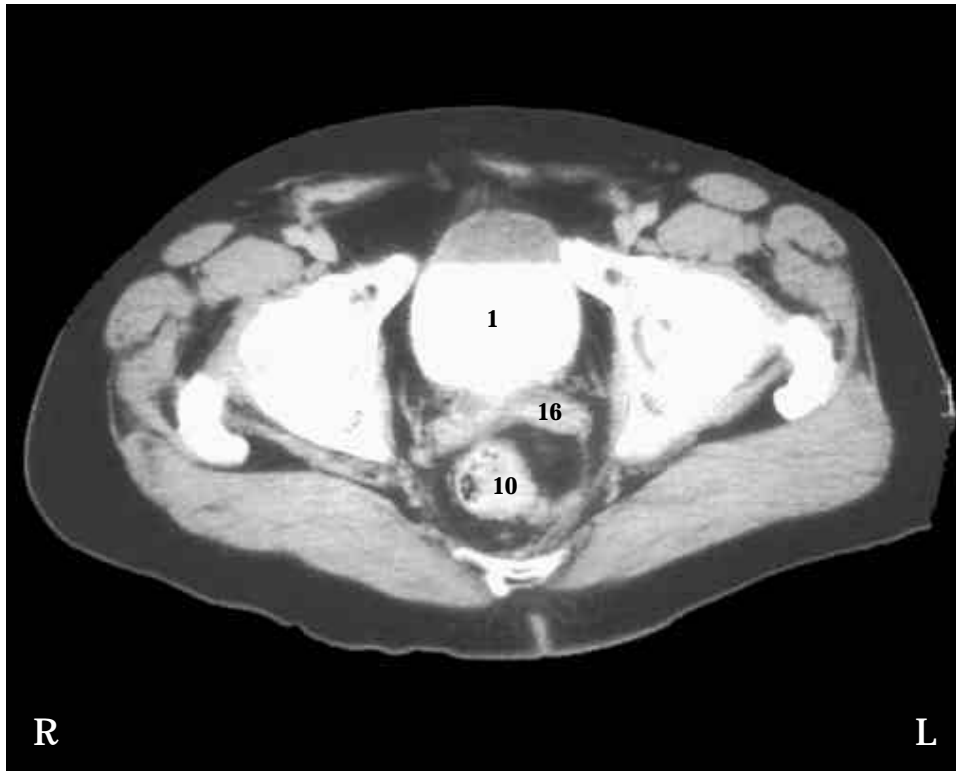
The gluteus maximus (9), gluteus medius (8), and gluteus minimus (7) continue inferiorly (SST Figure 11-28).

Skeletal System

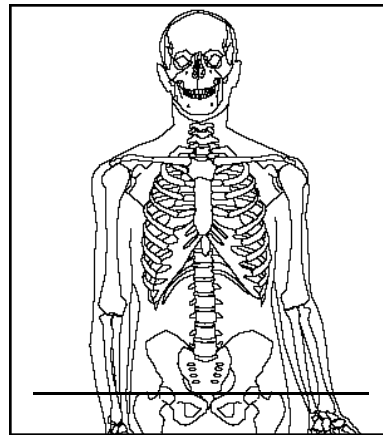
On the left side, the ilium (4), ischium (6), and pubis (3) of the coxa are cut, showing the head of the femur (5) within the acetabulum. The cut on the right side is at a slightly lower level, showing more of the femur head and the greater trochanter of the femur (12). The sacral hiatus (11) is posterior to the rectum (SST Figure 7-18, F and 28-1). Clinically, the sacral hiatus can be used as an entry way for the injection of anesthetic around spinal nerves within the sacral canal.

Urinary System

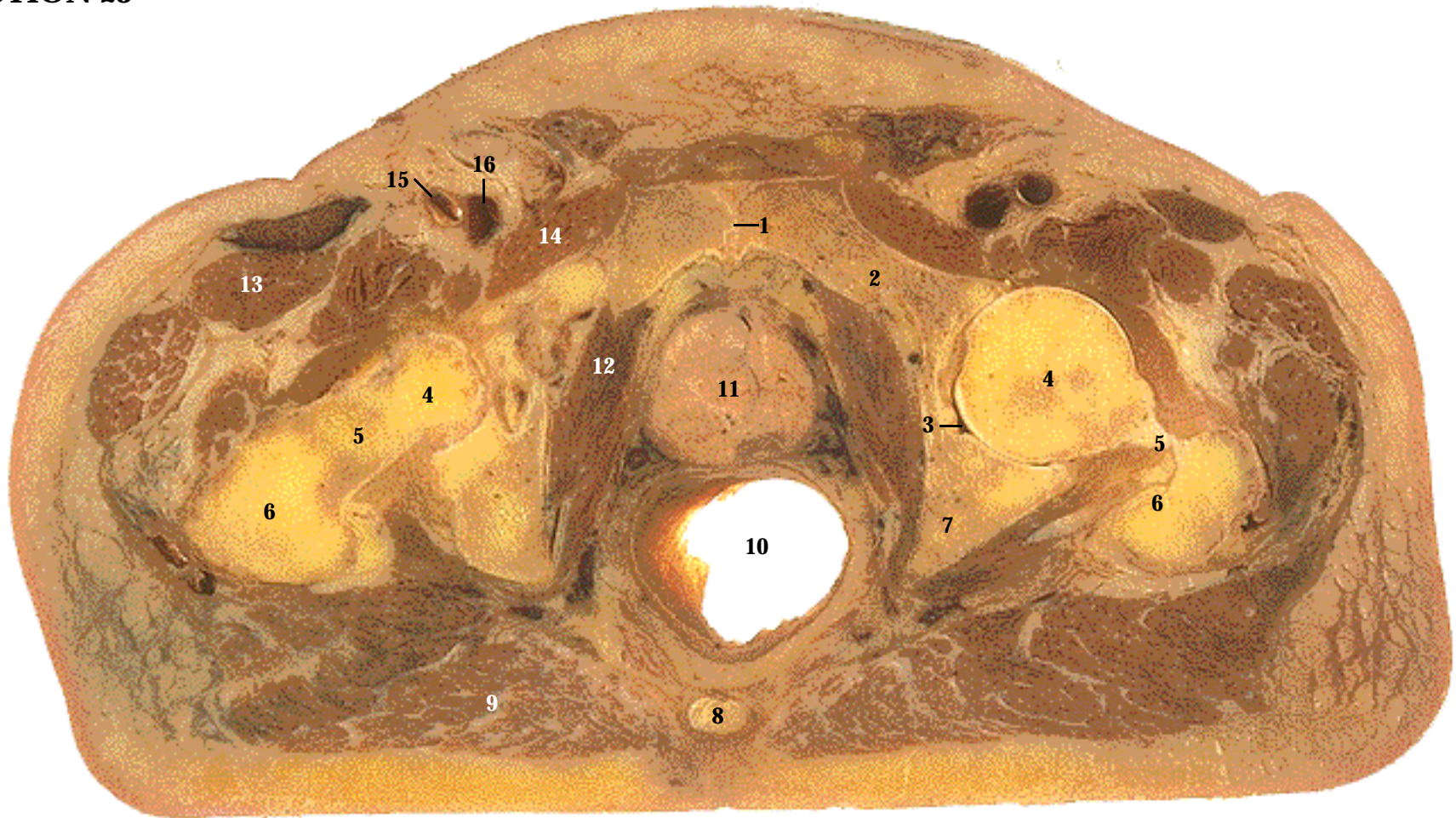
The urinary bladder (1) extends superiorly from the pelvic cavity (SST Figure 26-1). Note the thick muscular wall of the urinary bladder (SST Figure 26-7, C). The right ureter (2) can be seen connecting to the urinary bladder (SST Figure 28-1, A).



CT image. The urinary bladder (1) is almost completely filled with contrast medium. Note the following relationships: the urinary bladder is anterior, the rectum (10) is posterior, and the seminal vesicles (16) are between the urinary bladder and rectum. The seminal vesicles are just inferior to the venous plexus seen in the cadaver section.



Level: Through the sacrum at S5. The urinary bladder.



- | | | |
|--------------------------------|-------------------------------|---------------------------|
| 1. Symphysis pubis | 7. Ischium | 13. Anterior thigh muscle |
| 2. Pubis | 8. Coccyx | 14. Adductor muscle |
| 3. Acetabulum | 9. Gluteus maximus muscle | 15. Femoral artery |
| 4. Head of femur | 10. Rectum | 16. Femoral vein |
| 5. Neck of femur | 11. Prostate gland | 17. Urethra (CT only) |
| 6. Greater trochanter of femur | 12. Obturator internus muscle | |

Systemic Descriptions

Cardiovascular System

The external iliac artery has passed through the femoral sheath to become the femoral artery (15) (SST Figure 21-11). The femoral vein (16) is about to enter the femoral sheath and become the external iliac vein (SST Figure 21-19).

Digestive System

The sigmoid colon gives rise to the rectum (10) (SST Figure 24-14, A).

Muscular System

The obturator internus (12) is a lateral hip rotator (SST Figure 11-28, B). The adductor muscles (14) are separated from the anterior thigh muscles (13) by a connective tissue partition containing blood vessels and nerves (SST Figure 11-29). The gluteus maximus (9) continues inferiorly (SST Figure 11-28, A).

Reproductive System

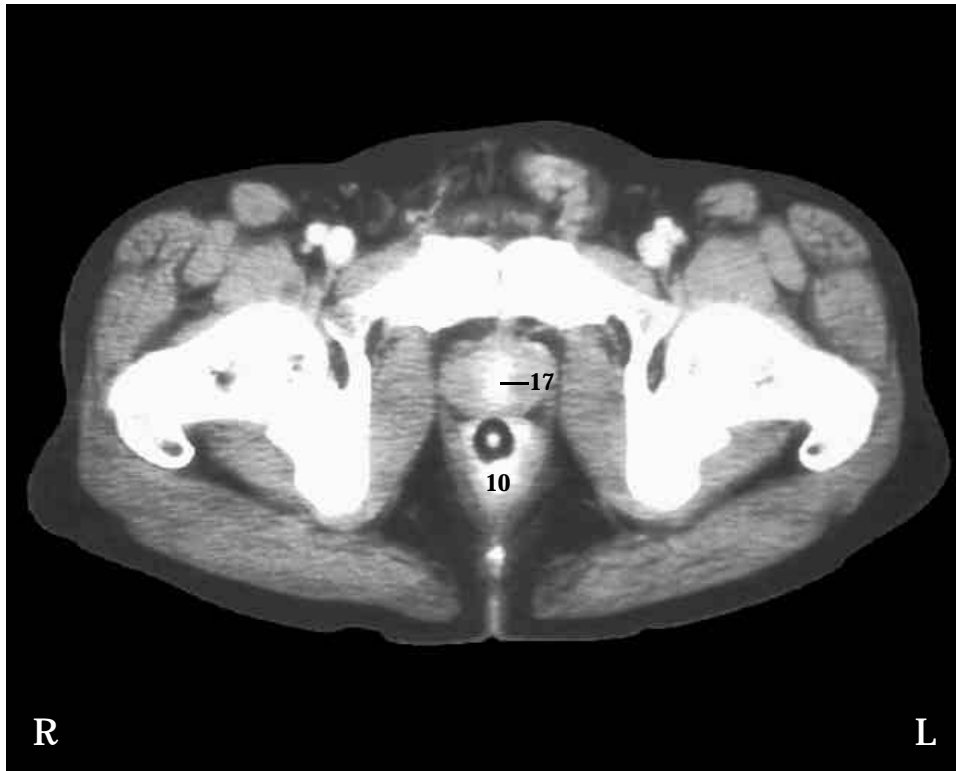The prostate gland (11) is located inferior to the urinary bladder and anterior to the rectum (SST Figure 28-1, A). A physician can check for a prostatic tumor by palpating (feeling) the prostate gland through the rectal wall.

Skeletal System

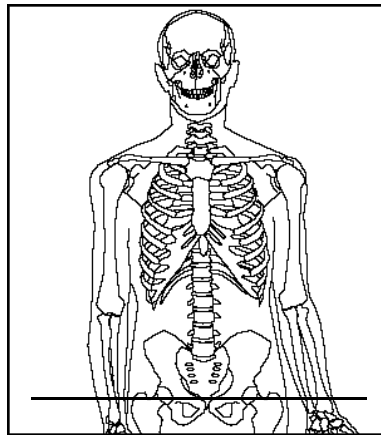
The head (4), neck (5), and greater trochanter (6) of the femur is cut (SST Figure 7-30). The head of the femur articulates with the acetabulum (3) of the coxa, which is sectioned through the pubis (2) and ischium (7) (SST Figure 7-27, B). Anteriorly, the two pubic bones are joined at the symphysis pubis (1) (SST Figure 7-26). The coccyx (8) is posterior to the rectum (SST Figure 7-15, A and 28-1).

Urinary System

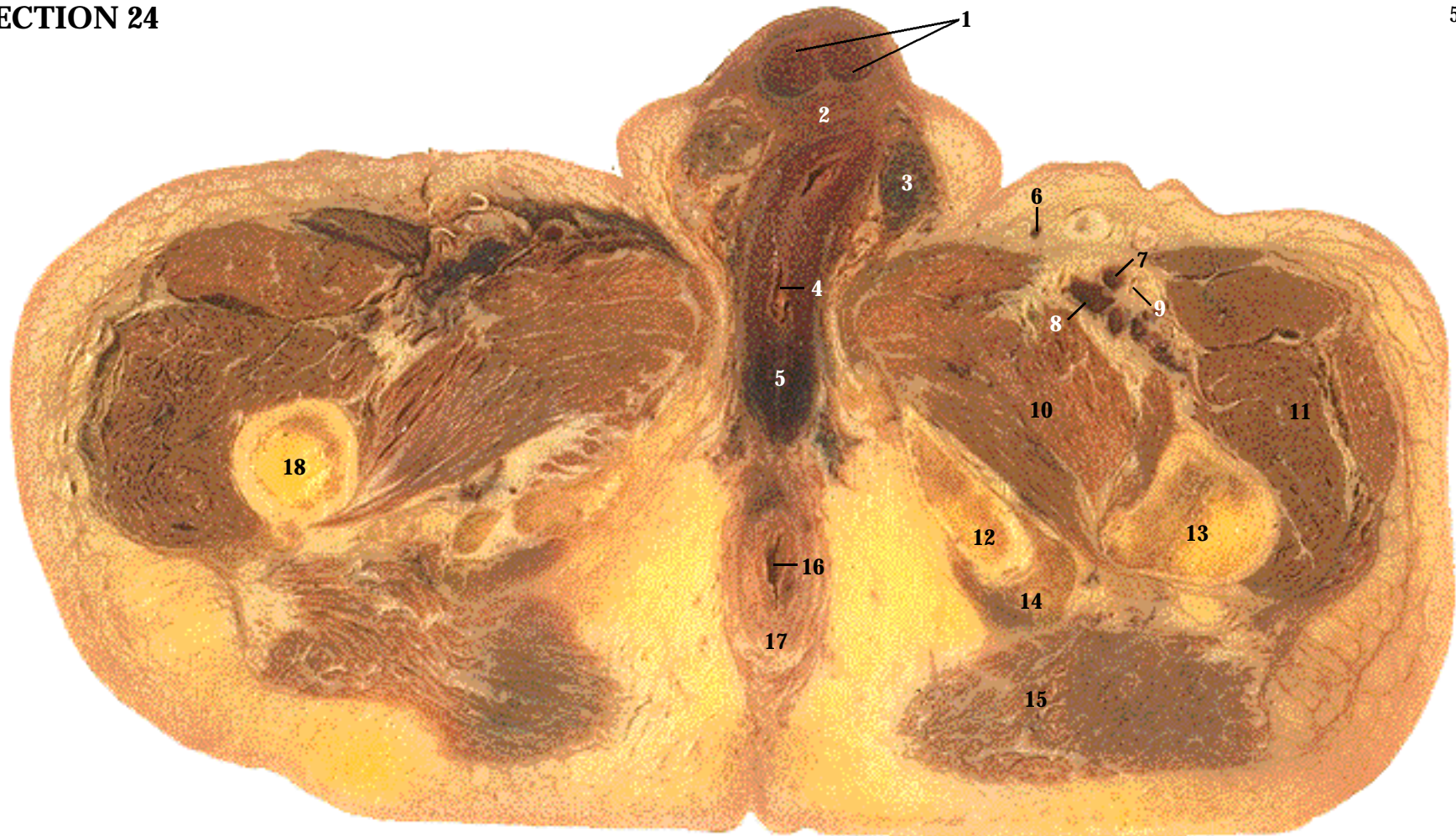
The prostatic urethra passes through the prostate gland (SST Figure 28-5). The urethra is collapsed and not visible in this section. A prostatic tumor can compress the urethra, making urination difficult.



CT image. The urethra (17) passes inferiorly through the prostate gland. A catheter within the urethra is used to inject contrast media into the urinary bladder. Note the white circle surrounded by black in the rectum (10). The white circle is a contrast-filled catheter used to inject contrast media into the digestive tract. The black circle is an air-filled balloon around a catheter, which helps to hold the catheter in place.



Level: Male pelvis, through the head of the femur.



- | | | |
|-------------------------|-----------------------------|------------------------------|
| 1. Corpora cavernosa | 8. Femoral vein | 15. Gluteus maximus muscle |
| 2. Corpus spongiosum | 9. Femoral nerve | 16. Anal canal |
| 3. Spermatic cord | 10. Adductor muscles | 17. External anal sphincter |
| 4. Spongy urethra | 11. Anterior thigh muscles | 18. Yellow marrow |
| 5. Bulb of penis | 12. Ischium | 19. Crura of penis (CT only) |
| 6. Great saphenous vein | 13. Femur | 20. Crena ani |
| 7. Femoral artery | 14. Posterior thigh muscles | 21. Nates |

Systemic Descriptions

Cardiovascular System

The femoral artery (7) continues inferiorly (SST Figure 21-11). The femoral vein (8) continues superiorly. The great saphenous vein (6) projects superiorly to join the femoral vein (SST Figure 21-19). The great saphenous vein is superficial and functions to drain superficial parts of the lower limb.

Digestive System

The anal canal (16) is surrounded by the external anal sphincter (17), which allows voluntary control of defecation (SST Figure 24-14, A). Enlarged veins under the skin in this region produce external hemorrhoids.

Muscular System

The adductor muscles (10) are separated from the anterior thigh muscles (11) by a connective tissue partition containing blood vessels and nerves (SST Figure 11-29). The gluteus maximus (15) (SST Figure 11-28, A) covers the posterior thigh muscles (14), which attach to the ischium (SST Figure 11-30)

Nervous System

The femoral nerve (9) is located lateral to the femoral artery (SST Figure 14-14).

Skeletal System

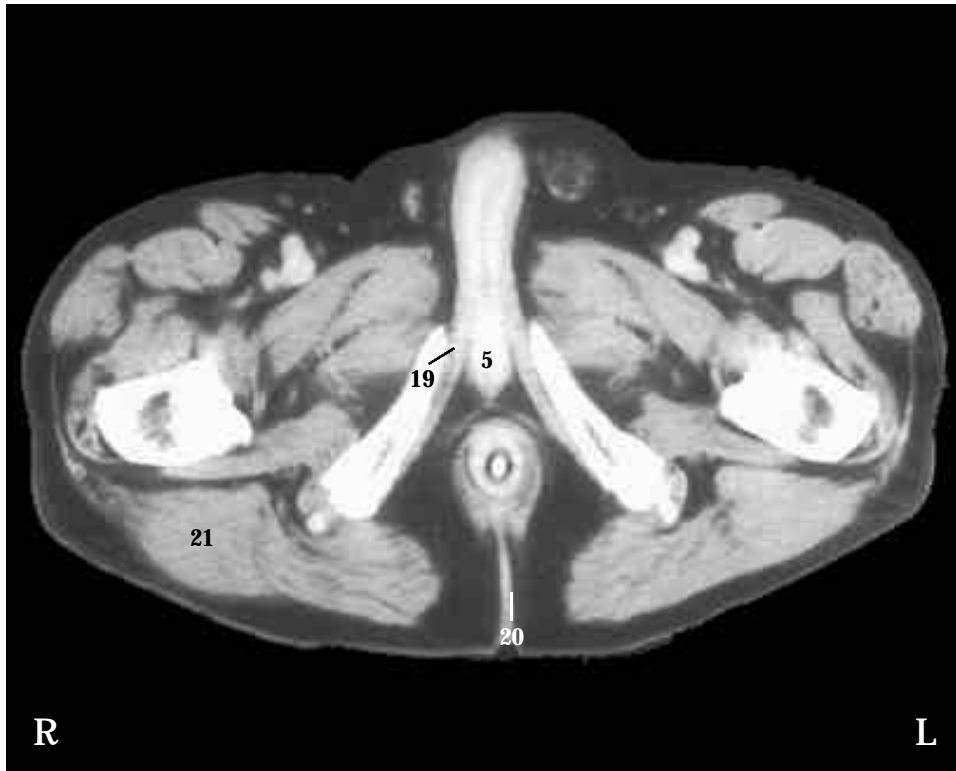
The ischium (12) and femur (13) can be seen (SST Figures 7-27, B and 7-30). Note the yellow marrow (18) within the medullary cavity of the femur (SST Figures 6-3 and 6-4)

Reproductive System

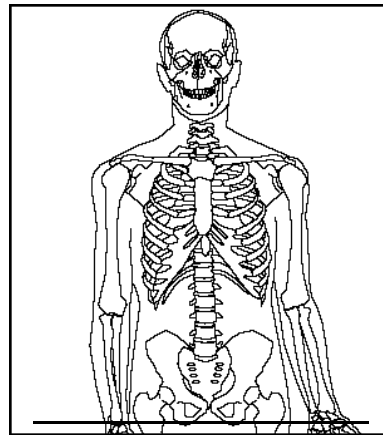
The corpora cavernosa (1) form the sides and dorsum of the penis. The corpus spongiosum (2) of the penis extends posteriorly to form the bulb of the penis (5) (SST Figure 28-6). The spermatic cords (3) connect inferiorly to the testes (SST Figure 28-5).

Urinary System

The spongy urethra (4) passes through the penis (SST Figure 28-6).

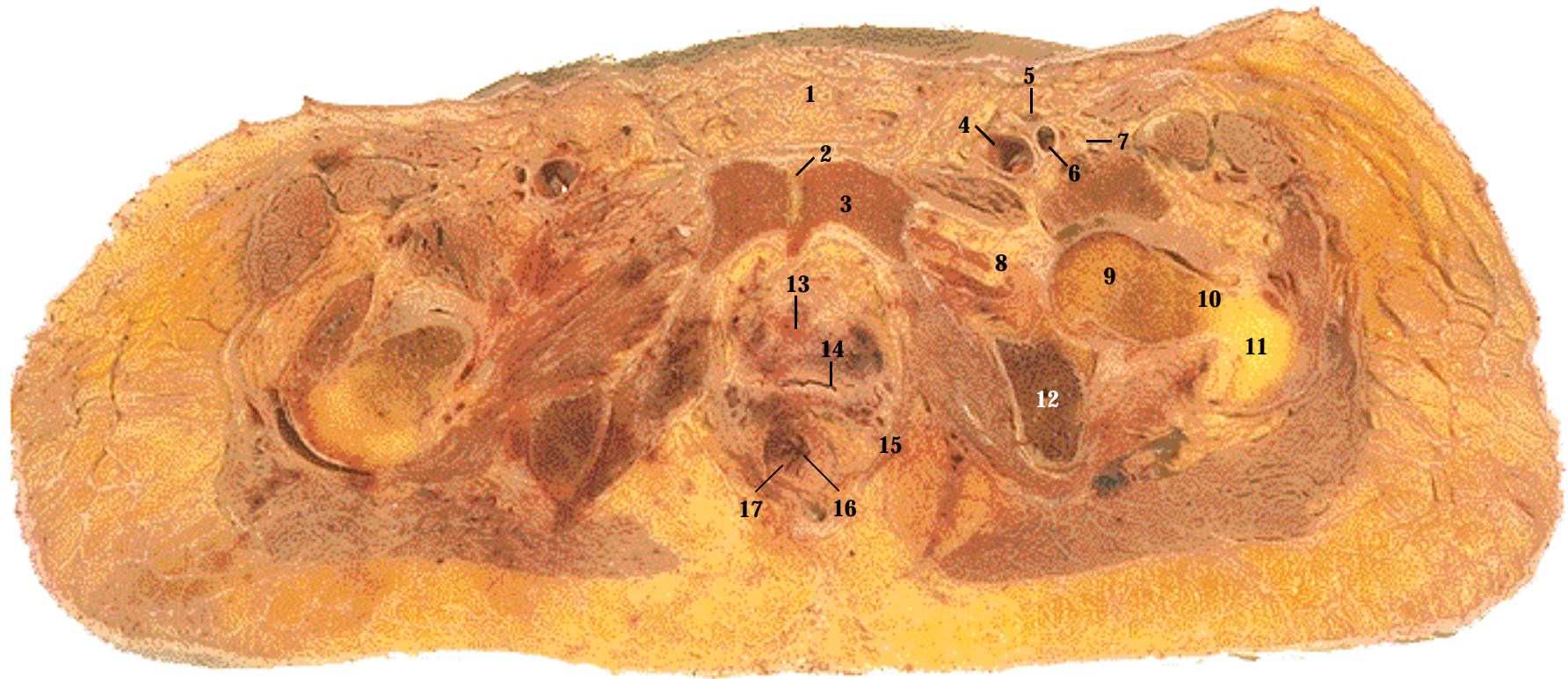


CT image. The CT shows the bulb (5) and crura (19) of the penis, which together form the root of the penis. Note the white circle surrounded by black in the anal canal (16). The white circle is a contrast-filled catheter used to inject contrast media into the digestive tract. The black circle is an air-filled balloon around a catheter, which helps to hold the catheter in place. Not normally seen in polite company, note the crena ani (20), also known as the cluneal cleft, which is between the nates (21).



Level: Male pelvis, through the inferior portion of the ischium.

SECTION 24



1. Mons pubis
2. Symphysis pubis
3. Pubis
4. Femoral vein
5. Great saphenous vein
6. Femoral artery
7. Femoral nerve

8. Obturator foramen
9. Head of femur
10. Neck of femur
11. Greater trochanter of femur
12. Ischium
13. Urethra
14. Vagina

15. Levator ani muscle
16. Anal canal
17. Anal columns
18. Urinary bladder (CT only)
19. Uterus (CT only)
20. Sigmoid colon (CT only)
21. Rectum (CT only)

Systemic Descriptions

Cardiovascular System

The femoral arteries (6) (SST Figure 21-11), femoral veins (4) and great saphenous veins (5) (SST Figure 21-19).

Digestive System

The anal canal (16) is present (SST Figure 24-14, A). Note the vertical anal columns (17). Enlargement of veins within the anal columns produces internal hemorrhoids.

Muscular System

The levator ani muscle (15) helps to form the pelvic floor (SST Figure 11-18, B). Parts of the levator ani can be named separately: the pubococcygeus extends between the pubic bone and coccyx, and more inferiorly, puborectalis wraps around the junction of the rectum and anus. The puborectalis pulls the inferior rectum anteriorly, keeping the anorectal junction closed, except during defecation, when the muscle relaxes.

Nervous System

The femoral nerve (7) is located lateral to the femoral artery (SST Figure 14-14).

Reproductive System

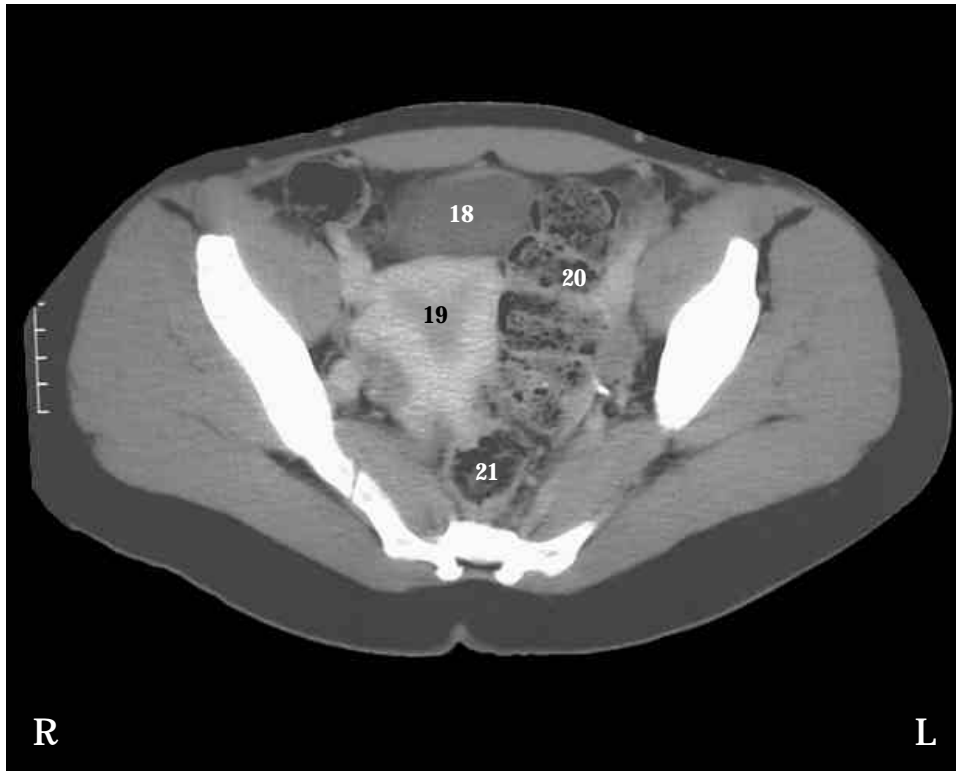
The vagina (14) is located anterior to the anal canal (SST Figure 28-8). The mons pubis (1) is anterior to the pubic bones (SST Figure 28-13).

Skeletal System

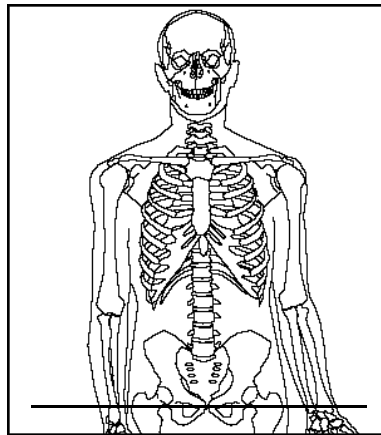
The head (9), neck (10), and greater trochanter (11) of the femur is cut (SST Figure 7-30). The coxa is sectioned through the ischium (12) and pubis (3). Note the obturator foramen (8), filled with connective tissue (obturator means occluded) (SST Figure 7-27, B). Anteriorly, the two pubic bones are joined at the symphysis pubis (2) (SST Figure 7-26).

Urinary System

The urethra (13) extends inferiorly (SST Figure 28-8). It passes through a small retropubic space filled with loose connective tissue and fat.



CT image. This CT is superior to the cadaver section. Note the urinary bladder (18) just posterior to the pubic bones. The pear-shaped uterus (19) is located centrally in the pelvic cavity. The sigmoid colon (20) extends to the rectum (21).



Level: Female pelvis through the pubic bones.

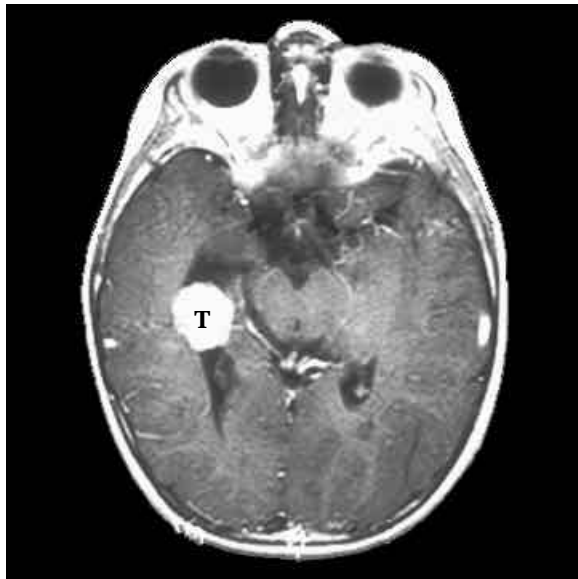


FIGURE 5A CHOROID PLEXUS PAPILLOMA T1 MRI. A papilloma is a nonspreading, benign epithelial tumor (T). Although not cancerous, these tumors can enlarge and compress surrounding tissues, impairing their normal function. It can also impair cerebrospinal fluid flow, producing hydrocephalus (see Figure 6).

Level: Transverse section through the orbits, midbrain, and lateral ventricles. Compare to Section 3.

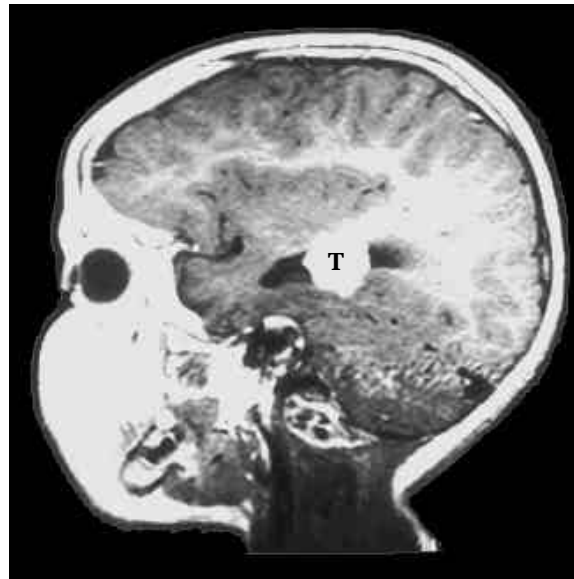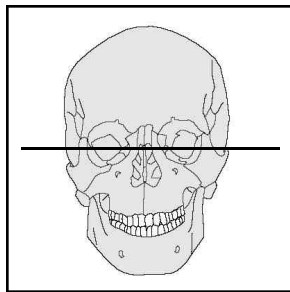


FIGURE 5B The choroid plexuses consist of specialized epithelial cells, connective tissue, and blood vessels. The specialized epithelial cells are called ependymal cells. The choroid plexuses produce cerebrospinal fluid, which is secreted into brain spaces called the ventricles.

Level: Sagittal section through the right orbit. Compare to Figure 3.

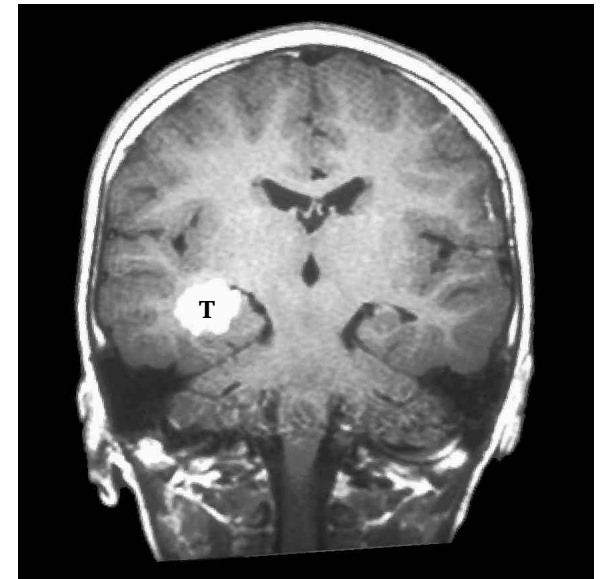
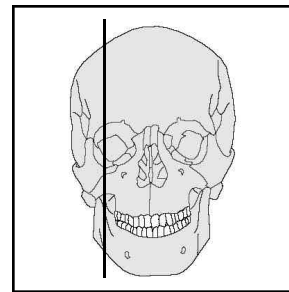
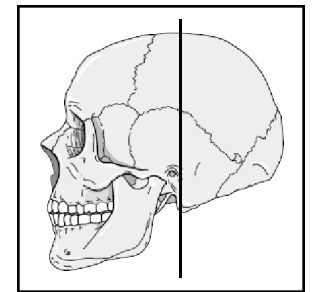


FIGURE 5C Typically, these papillomas form in the lateral ventricles in children, and the fourth ventricle in adults. This series of magnetic resonance images demonstrates the power of the computer to reconstruct an image in three different planes.

Level: Frontal section near the external auditory meatus. Viewed from the front. Compare to Figure 4.



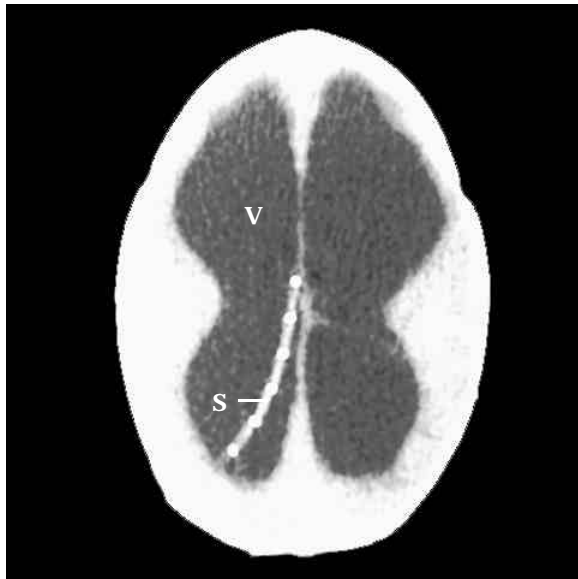


FIGURE 6 HYDROCEPHALUS

CT image. Hydrocephalus is an accumulation of cerebrospinal fluid within brain spaces called the ventricles (V). The increased fluid volume produces pressure that expands the ventricles and compresses brain tissue. The shunt (S) seen in the CT is a drainage tube that removes cerebrospinal fluid from the ventricles.

Level: Through the superior part of the braincase. Compare to Section 1.

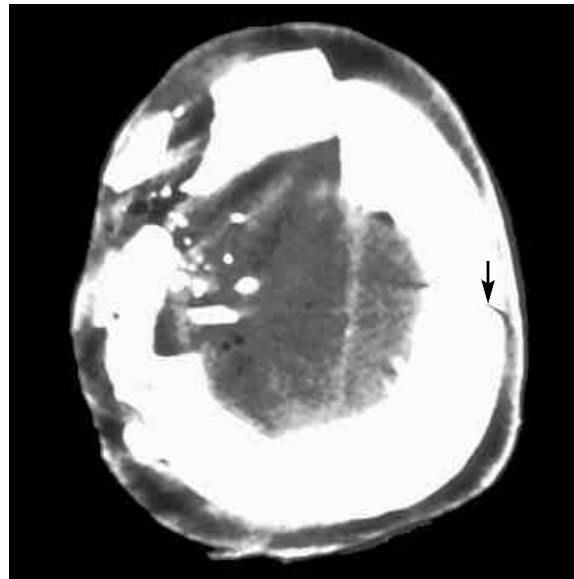
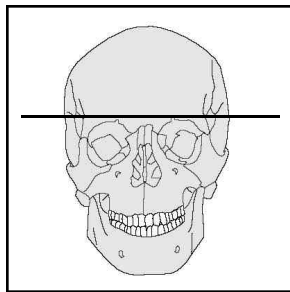


FIGURE 7 GUNSHOT TO THE HEAD

CT image. A bullet has entered the left side of the skull (arrow). The exit wound on the right side is larger than the entry wound. Note the massive fractures of the skull bones, with accompanying bone and bullet fragments.

Level: Through the superior part of the braincase.

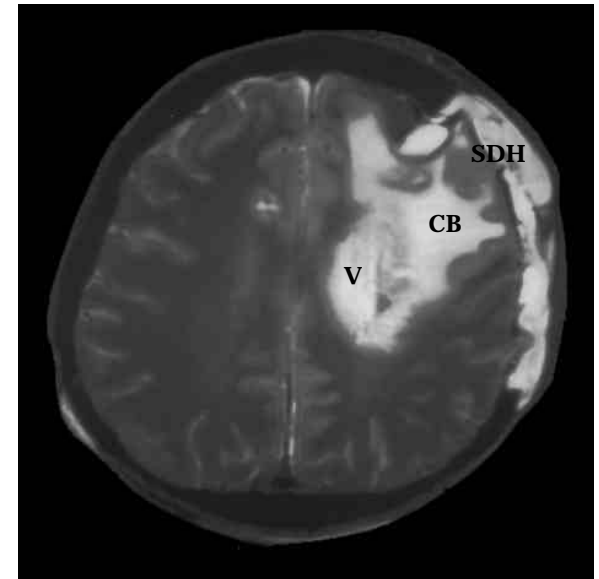
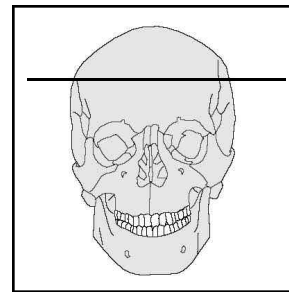


FIGURE 8 CEREBRAL HEMORRHAGE

T2 MRI. Nonflowing blood appears white in a T2 MRI. Trauma to the head has produced a subdural hematoma (SDH), and a cerebral bleed (CB) has resulted in an accumulation of blood that has also filled a lateral ventricle (V).

Level: Through the superior part of the braincase.

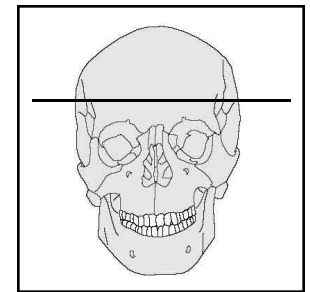

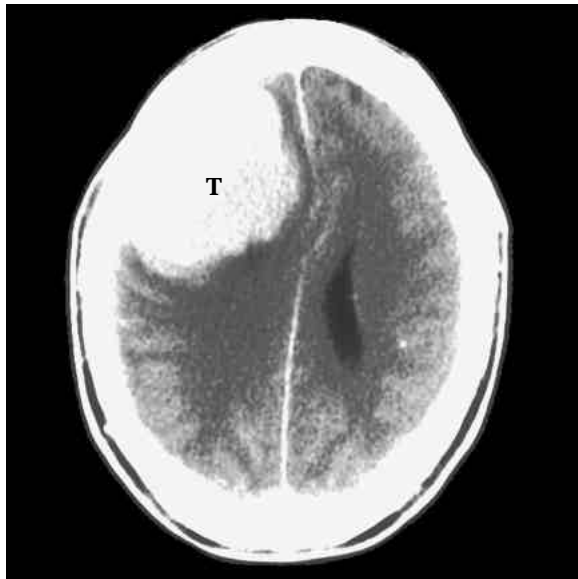


FIGURE 9 MENINGIOMA T1 MRI. The meninges are three membranes surrounding the brain and spinal cord. From superficial to deep, the meninges are the dura mater, arachnoid, and pia mater. A meningioma is a benign, encapsulated tumor (T) that arises from the arachnoid. This meningioma is compressing the surrounding nervous tissue.

Level: Through the superior part of the braincase. Compare to Section 1.

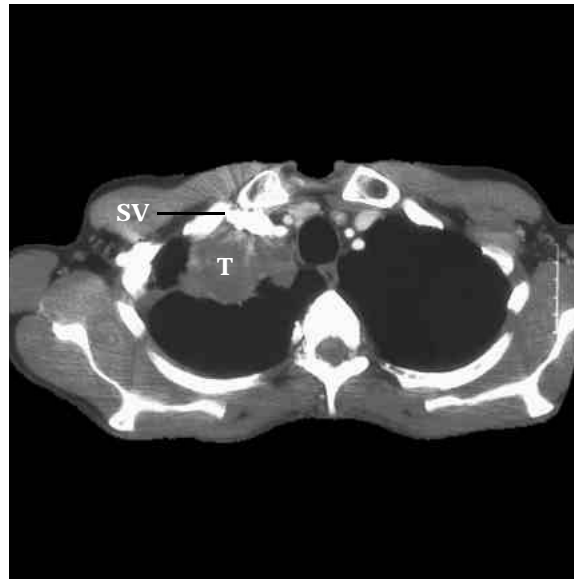
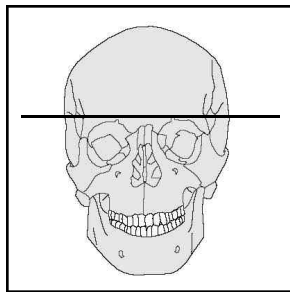


Figure 10 LUNG TUMOR CT image. Cancerous lung tumor in a person who chronically smoked. The tumor has partially occluded the subclavian vein (SV), which is filled with contrast medium.

Level: Through T3. Compare to Section 10.

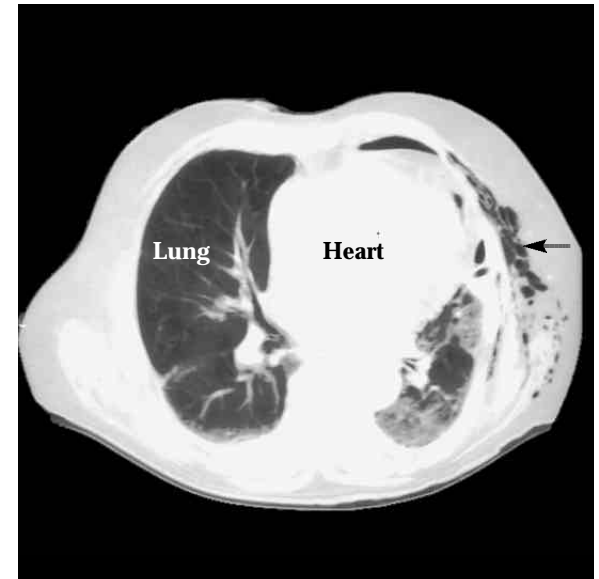
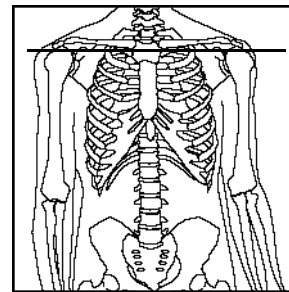
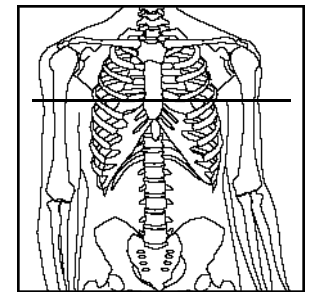


FIGURE 11 PNEUMOCYSTIC PNEUMONIA CT image emphasizing lung connective tissue. Pneumocystic pneumonia occurs in individuals with depressed immunity, such as AIDS patients. The right lung is normal, whereas the left lung has become dense and fibrotic. Lung damage has also resulted in air (black) escaping into tissues outside the ribs (arrow).

Level: Through T8. Compare to Section 13.



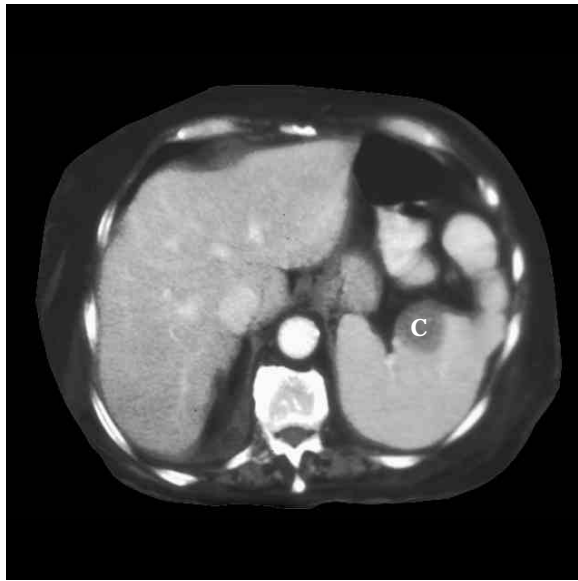


FIGURE 12 SPLENIC MASS CT image. CT scan of the spleen is considered the best tool for diagnosing splenic disorders such as tumors, abscesses, or cysts (C).

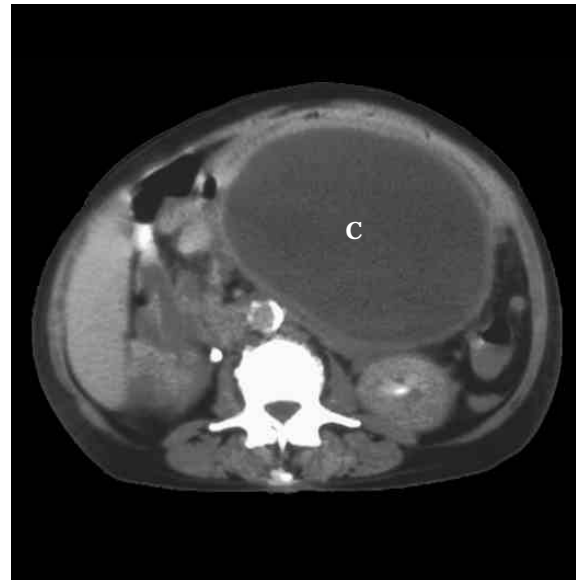


FIGURE 13 PANCREATIC CYST CT image. The cyst (C) contains pancreatic juices and dead tissue. Pancreatic cysts are commonly found in cases of chronic pancreatitis. Leakage and activation of pancreatic juices within the pancreas results in the digestion and destruction of the pancreas. Often found in chronic alcoholics.

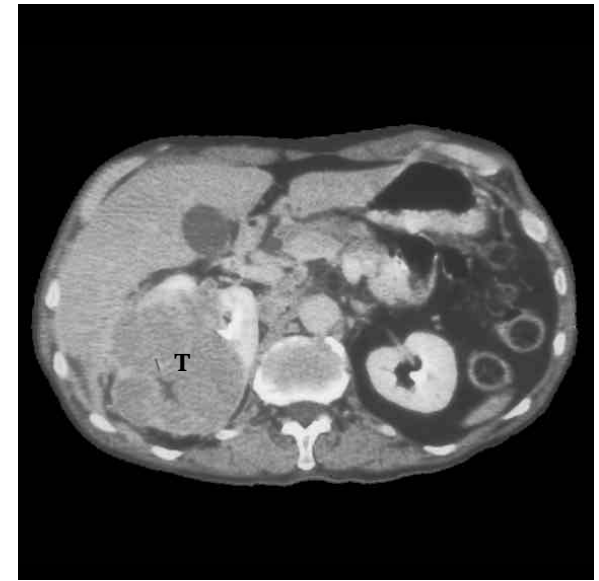
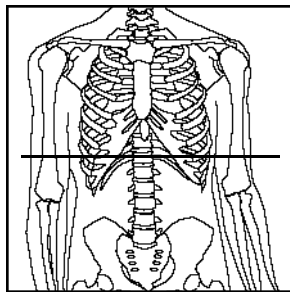
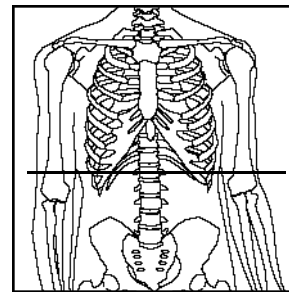


FIGURE 14 RENAL CARCINOMA CT image. Renal cancer is responsible for about 3% of cancers. If the cancer is confined to the kidney, removal of the kidney results in a five-year survival rate of 50% to 80%. If the tumor (T) is locally invasive, as in this case, the survival rate drops to 25% to 50%.

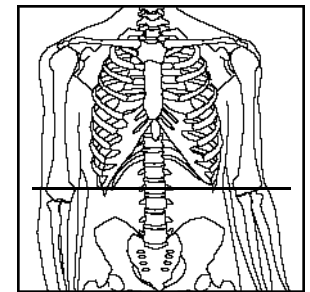
Level: Level:
Through T12.
Compare to Section
16



Level: Through L1.
Compare to Section
17.



Level: Through L2.
Compare to Section
18.



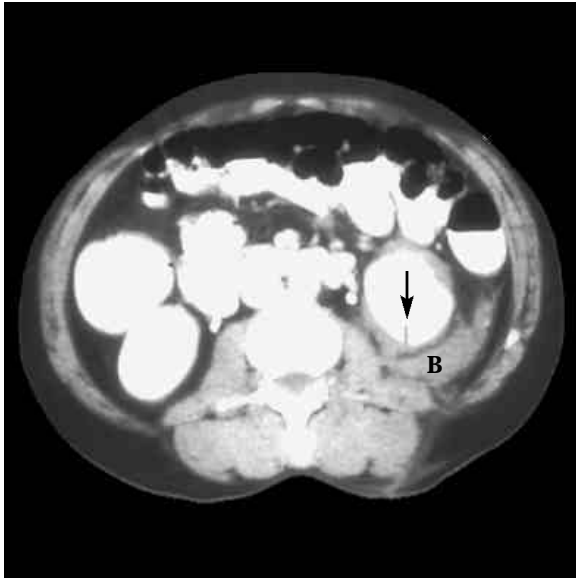


FIGURE 15 KNIFE WOUND TO KIDNEY CT image. The arrow indicates the location where the left kidney has been damaged by a knife. Note the bleeding (B) around the kidney.

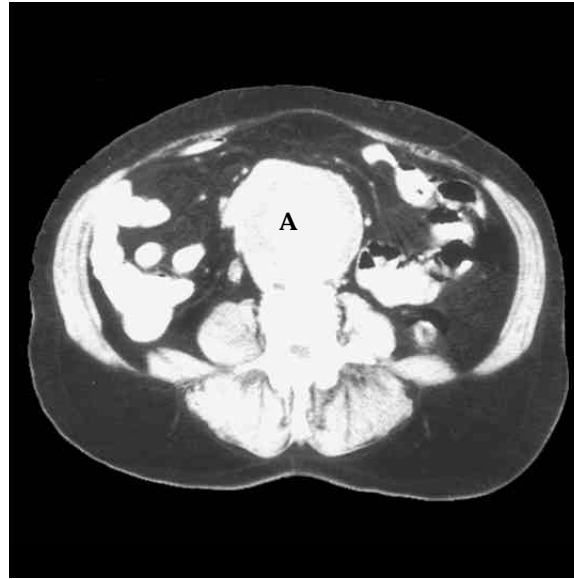
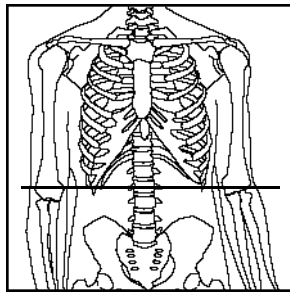


FIGURE 16 AORTIC ANEURYSM CT image. An aneurysm (A) is a dilation of an artery (SST p. 673). As the artery enlarges, the danger increases that the artery will rupture (SST p. 694). A rupture of the aorta usually results in death. In the brain, a rupture can cause a stroke (SST p. 430).

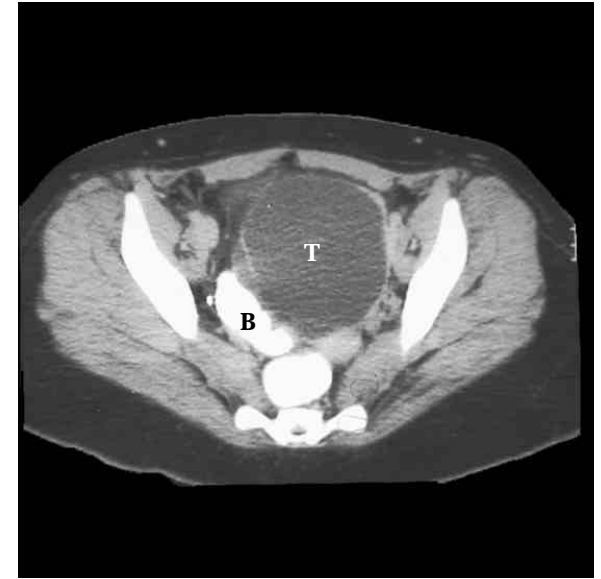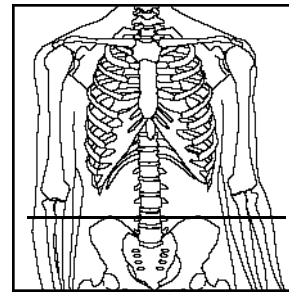


FIGURE 16 PELVIC MASS CT image. A large pelvic tumor (T) is compressing the urinary bladder (B).

Level: Through L2.
Compare to Section 19.



Level: Through L4.
Between Sections 19 and 20.



Level: Through the sacrum at S3.
Compare to Section 21.

